

Isolated Right-Sided Infective Endocarditis—An Infected Right Ventricular Myxoma Masquerading as “Tricuspid Vegetation”—A Case Report

Ramachandran Muthiah

Thoothukudi Medical College Hospital, Thoothukudi, India

Email: cardioramachandran@yahoo.co.uk

How to cite this paper: Muthiah, R. (2018) Isolated Right-Sided Infective Endocarditis—An Infected Right Ventricular Myxoma Masquerading as “Tricuspid Vegetation”—A Case Report. *Case Reports in Clinical Medicine*, 7, 182-209.
<https://doi.org/10.4236/crcm.2018.73017>

Received: January 30, 2018

Accepted: March 5, 2018

Published: March 8, 2018

Copyright © 2018 by author and Scientific Research Publishing Inc. This work is licensed under the Creative Commons Attribution International License (CC BY 4.0).

<http://creativecommons.org/licenses/by/4.0/>



Open Access

Abstract

Aim: To report a case of right ventricular myxoma prolapsing through the tricuspid valve with an attachment of vegetation in a 3-year-old male child.

Introduction: Right-sided endocarditis commonly involves the tricuspid valve. Low pressure and low oxygen saturation in the right sided cardiac chambers protect the tricuspid and pulmonary valves from being subjected to excessive strained and damage occurs from injected particulate matter, contaminated venous lines and drug solutions causing endocarditis. RV (right ventricular) myxoma harboured the infection due to trauma as a result of friction movement across the tricuspid valve. **Case Report:** A 3-year-old male child having the spikes of fever for 2 weeks, presented with tumor “plop” and 3/6 systolic murmur in lower left sternal border and echocardiography revealed a tumor-mimicking vegetation visible as a mass lesion across the tricuspid valve, which is attached to the interventricular septum by a pedicle suggesting a RV myxoma. The vegetation was found to be attached with the tumor and it disappeared with antibiotics and aspirin therapy and the child was advised surgical removal of the tumor. **Conclusion:** A diagnosis of infective endocarditis can be made in tricuspid valve dysfunction with a floating mass and fever. The cardiac myxoma with an attached vegetation is masquerading as vegetation mass on transthoracic echocardiography in this child.

Keywords

RV Myxoma, Vegetation, Tricuspid Regurgitation, Aspirin Therapy, AngioVac

1. Introduction

Infective endocarditis (IE) is a microbial infection of the endocardial (endothelial) surface of the heart. It accounts for about 0.75 admissions per 1000 per year in large community hospitals [1] and a population based incidence of 4 - 10 per 100,000 per year, with a slightly higher rate in men [2] [3]. Children with underlying cardiovascular disease may develop endocarditis at any age. It is most frequent on the left side of the heart [4]. Right-sided infective endocarditis is relatively rare and occurring in 5% - 10% of cases [5]. It involves the tricuspid valve in 90%, pulmonary valve in <10% of cases [6] and predominantly occurs in intravenous drug users. The majority of cases of neonatal infective endocarditis are right-sided and occur on structurally normal hearts [7], probably due to increased use of prosthetic intravascular devices and indwelling venous catheters [8].

Tricuspid valve infective endocarditis accounts for 2.5% - 3.1% of IE cases [9]. The right-sided infective endocarditis involving the right ventricular myxoma, prolapsing through tricuspid valve is uncommon and so this case had been reported.

2. Case Report

A 3-year-old male child with 2 weeks fever was referred for echocardiographic evaluation. His pulse rate was 112 bpm with a temperature elevation up to 101°F. Blood chemistry revealed leukocytosis with an elevation of total count up to 42,700 cells/cubic mm of blood (normal—6000 to 18,000 cells/cubic mm of blood), Polymorphs—80% (normal—50% to 70%), Lymphocytes—17% (normal—20% to 40%), Eosinophils—3% (normal—2% to 6%), Platelets—2.27 lakhs/cubic mm of blood (normal—1.5 to 4.5 lakhs/cubic mm of blood). The child was mildly anemic normochromic, normocytic red blood cell indices (Hb—7.7 gm% (normal-13 to 16 gm/dl). ESR (erythrocyte sedimentation rate) was elevated—48 mm/hour (normal—0 to 20 mm/hr). Serum rheumatoid factor (RA factor) was negative (which may be detected in 50% of cases). Blood widal, Dengue antibody test, smear for malarial parasites and blood cultures were negative. Urinalysis revealed no microscopic hematuria. He had no other features of infective endocarditis such as Osler's nodes, Janeway lesions, Roth spots, splinter hemorrhages which are relatively rare in children and no spotty skin pigmentation, a characteristic feature of myxoma in Carney complex. Abdominal examination revealed no splenomegaly (which occurs only in 10% to 15% of cases). ECG and X-ray chest PA (postero-anterior) were normal as shown in **Figure 1** and **Figure 2**. Physical examination revealed a grade 3/6 systolic murmur which increases with inspiration (Carvallo's sign) and an early diastolic tumor "plop" due to abrupt diastolic seating of a mass in the right atrioventricular orifice [10] in the lower left sternal border on auscultation. 2 D echocardiography revealed a large, mobile homogeneous mass in the tricuspid orifice, visible as a "tumor-mimicking vegetation" as shown in **Figures 3-9**.

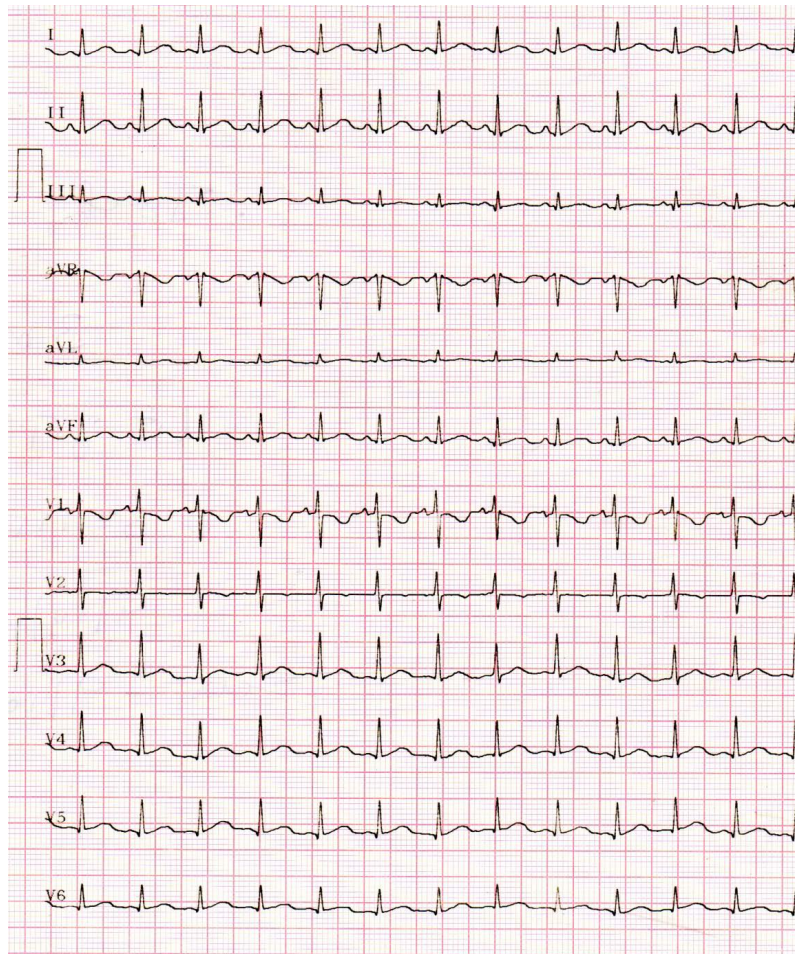


Figure 1. ECG revealed a heart rate of 112 bpm due to fever.

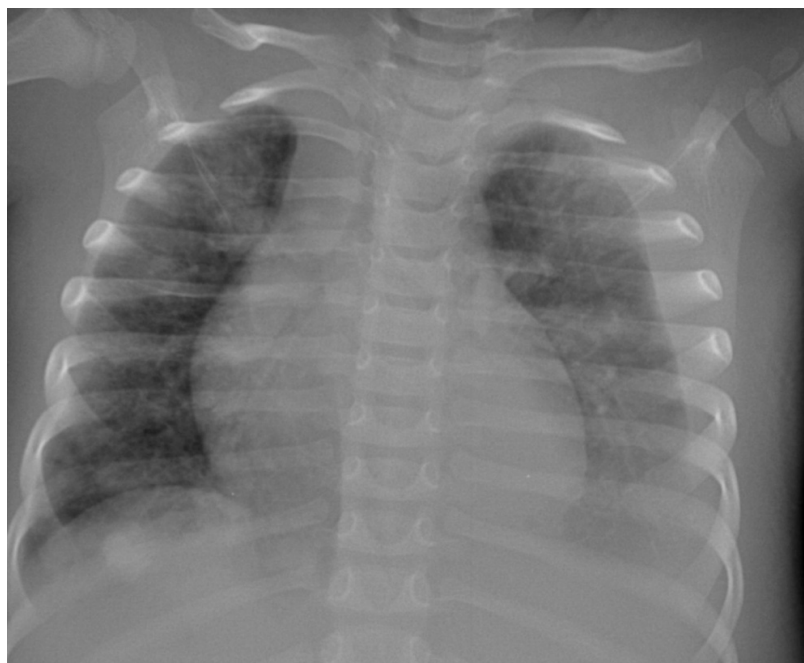

Figure 2. X-ray chest PA (postero-anterior) view revealed normal.

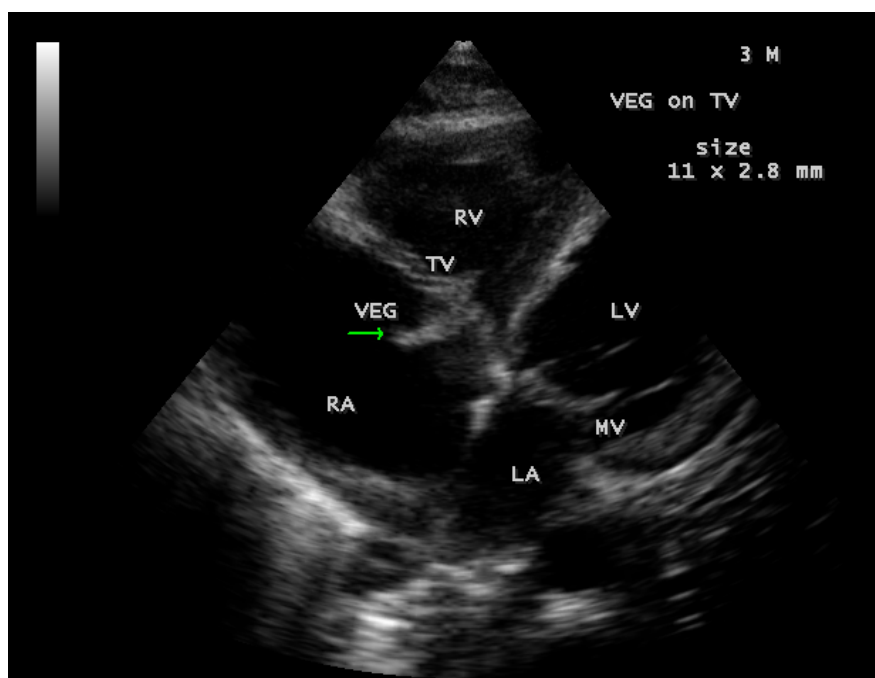


Figure 3. Showing the vegetation prolapsing through the tricuspid valve (arrow) in a 3-year-old male child.

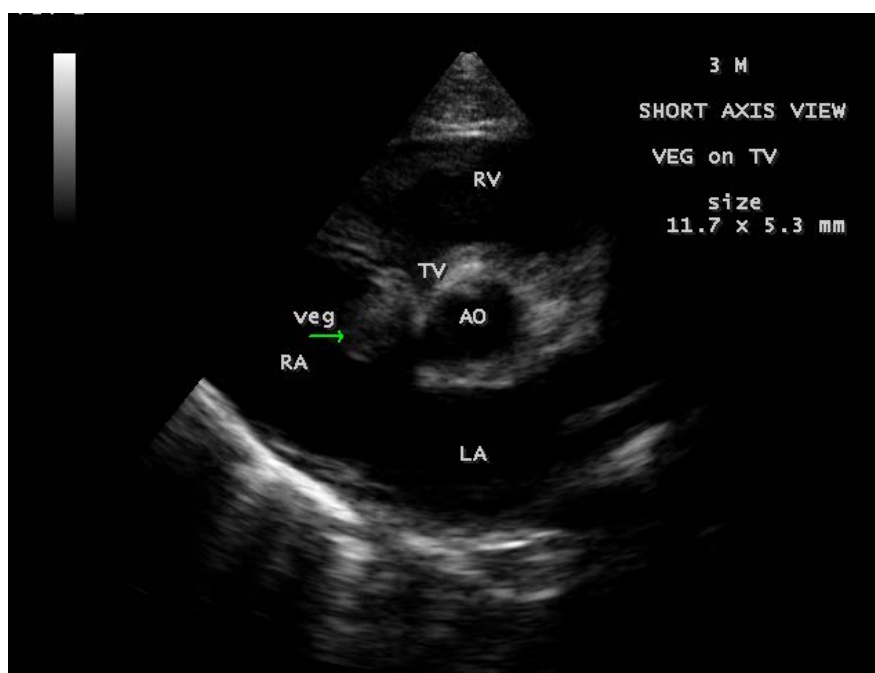


Figure 4. Short axis view showing the vegetation prolapsing through the tricuspid valve (arrow) in a 3-year-old male child.

An irregular homogeneous hypodense mass suggesting a vegetation was attached to the mass, which is globular shape and a heterogeneous or mottled appearance throughout, with echolucent areas representing hemorrhage or necrosis suggesting a myxoma [12] as shown in **Figures 10-12**.

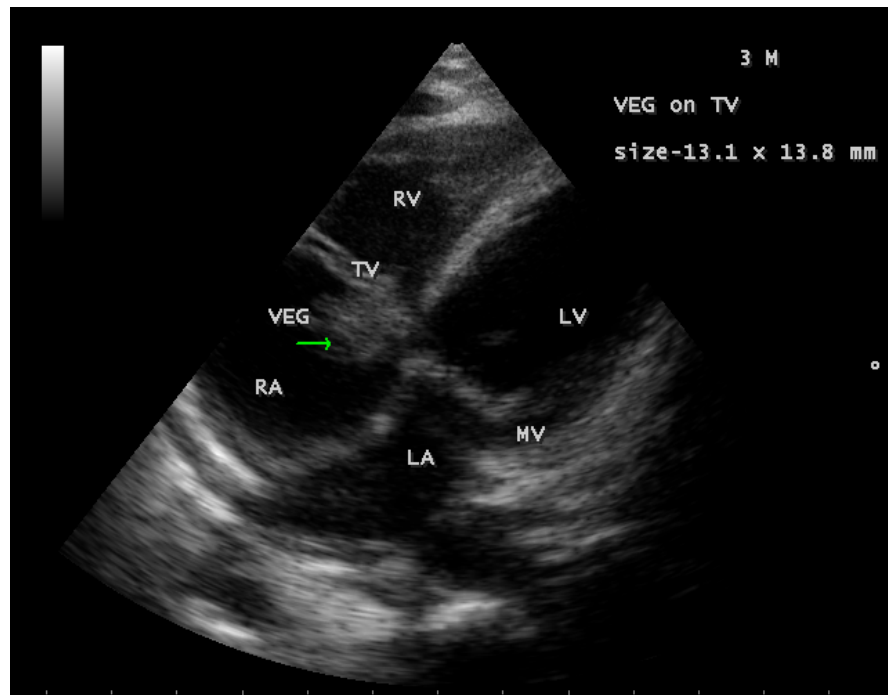


Figure 5. Showing the tumor-mimicking vegetation (arrow) in a 3-year-old male child.

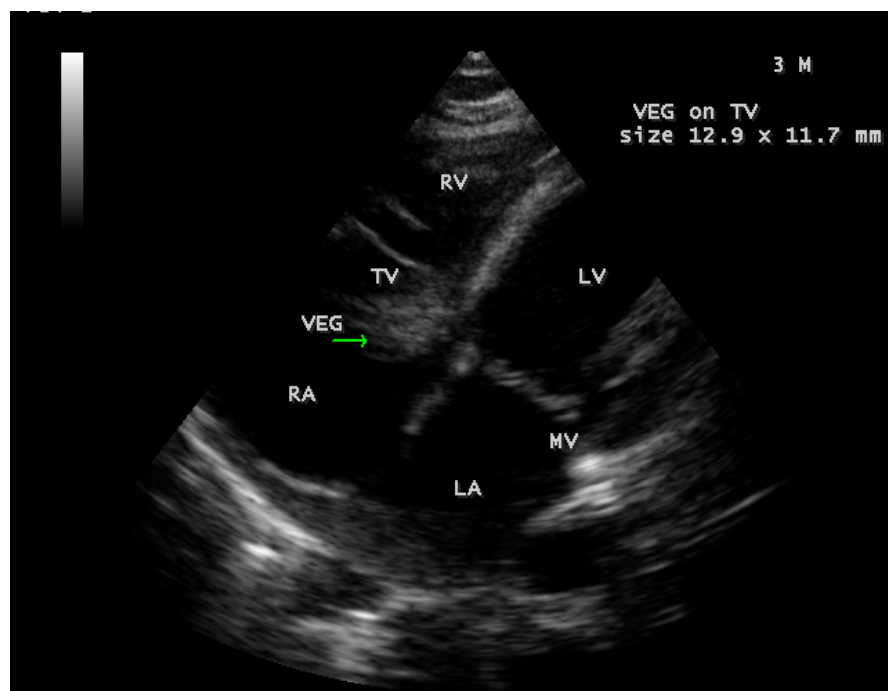


Figure 6. Showing the tumor-mimicking vegetation (arrow) in a 3-year-old male child.

The mass was attached to the interventricular septum by a pedicle (stalk), protruding through the tricuspid valve and appear as “cluster of grapes” [13] as shown in **Figure 13** and **Figure 14**, suggesting a RV (right ventricular) myxoma.

The mass produces a traumatic regurgitation across the tricuspid valve due to friction movement as shown in **Figures 15-17**.

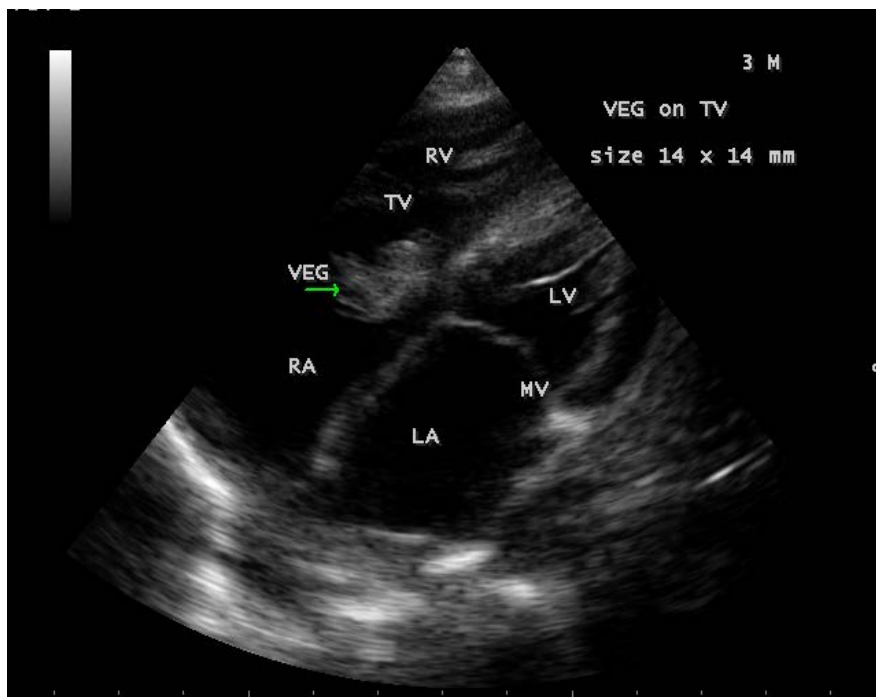


Figure 7. Showing the tumor-mimicking vegetation (arrow) in a 3-year-old male child.

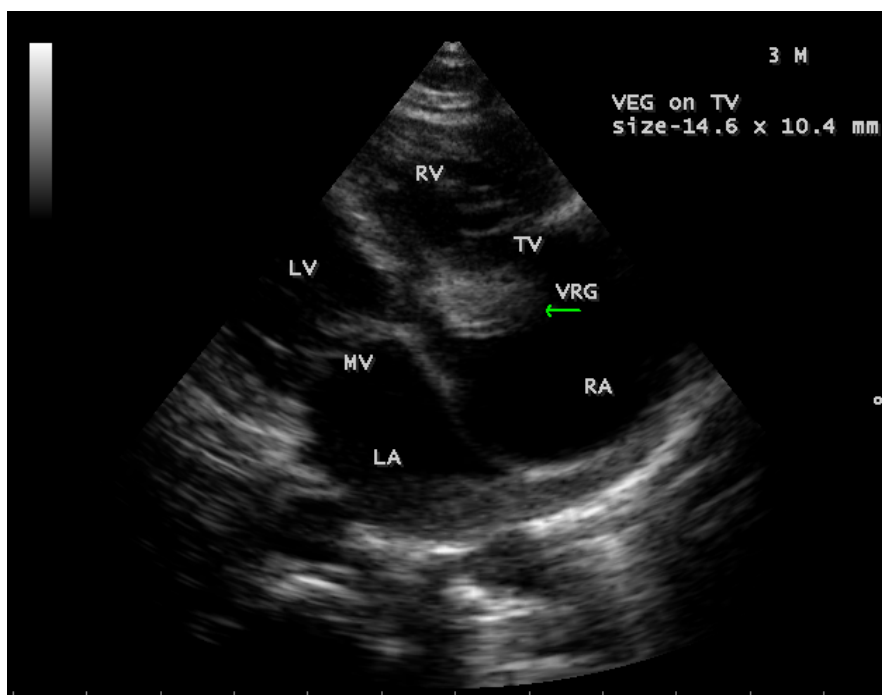


Figure 8. Subcostal view showing the tumor-mimicking vegetation (arrow) in a 3-year-old male child.

The child was treated with a course of intravenous ceftriaxone (250 mg twice daily) combined with gentamycin (20 mg twice daily) along with oral aspirin therapy (75 mg daily) for a period of 10 days, the tricuspid regurgitation decreases as in **Figure 18** and the vegetation was found to be disappeared as shown

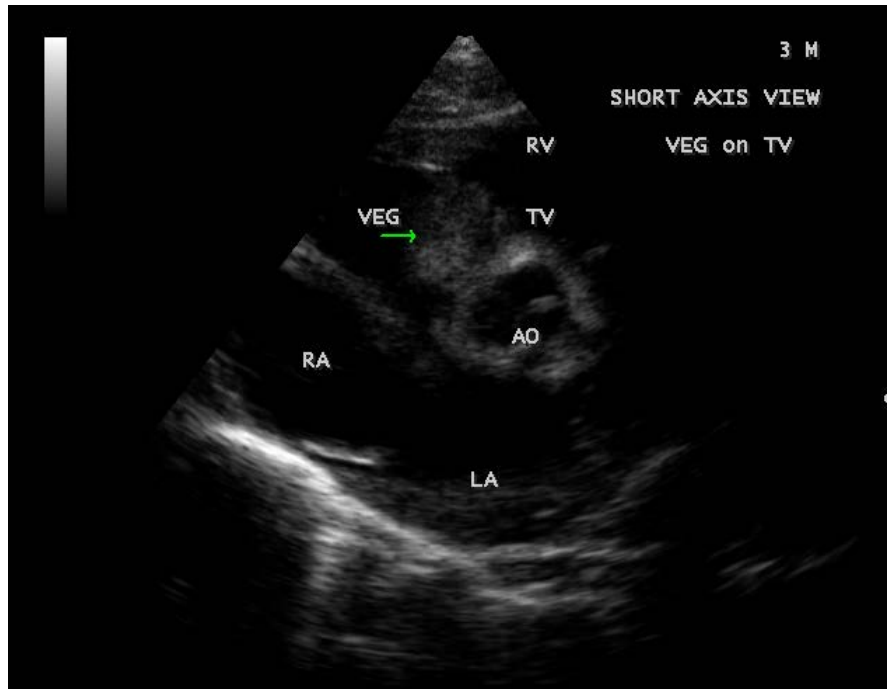


Figure 9. Short axis view showing the tumor-mimicking vegetation (arrow) in a 3-year-old male child [11].

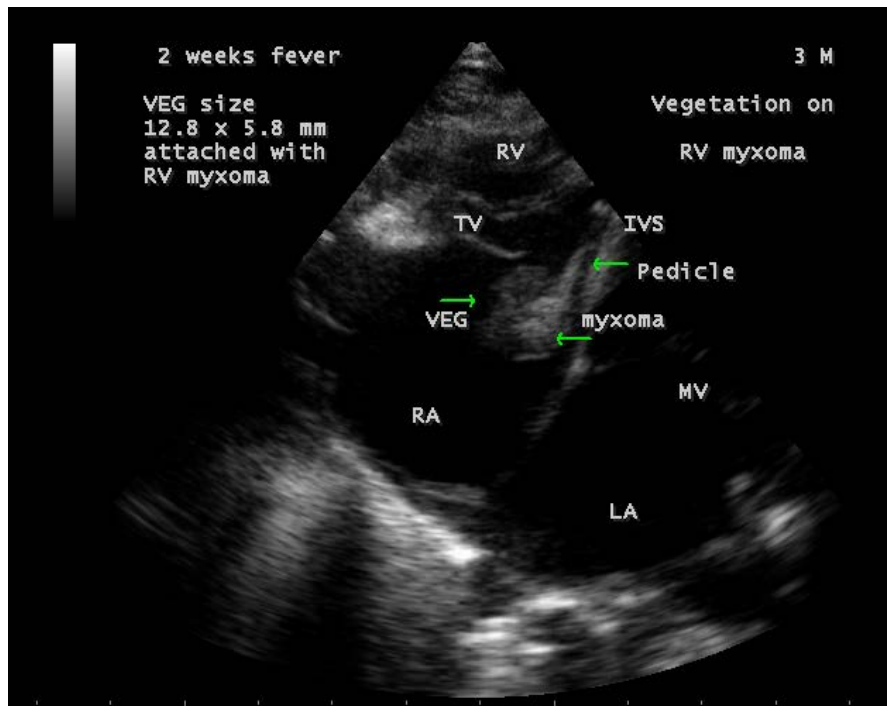


Figure 10. Showing a vegetation (right arrow) attached to the myxoma (lower left arrow) in a 3-year-old male child. Upper left arrow showing the pedicle of myxoma attached to the interventricular septum (IVS).

in **Figure 19**. The child was symptom free and advised periodic echocardiographic evaluation with a continuation of medications up to 4 weeks period and

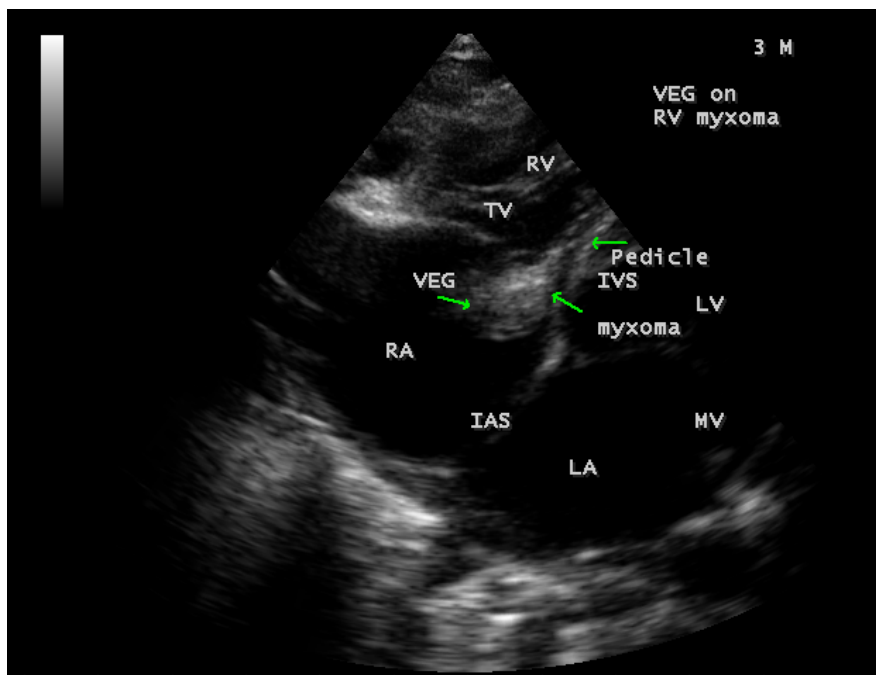


Figure 11. Showing the myxoma (lower left arrow) with vegetation (right arrow) in a 3-year-old male child. Upper left arrow showing the pedicle of myxoma attached to the interventricular septum (IVS).

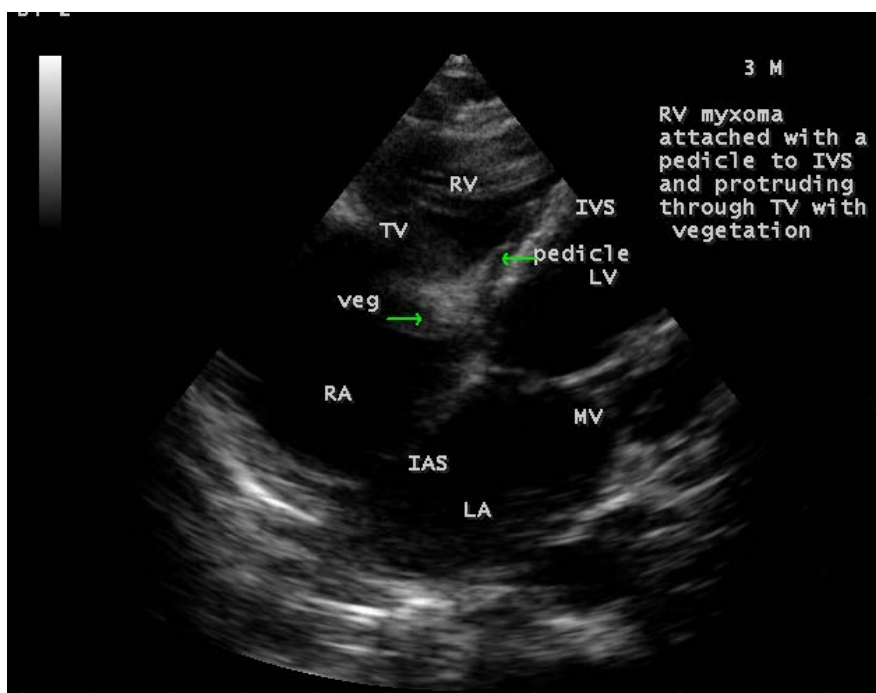


Figure 12. Showing the myxoma with vegetation (right arrow) in a 3-year-old male child. Upper left arrow showing the pedicle of myxoma attached to the interventricular septum (IVS).

early surgical removal of the tumor. On follow-up, the child died due to a syn-
copal episode before the surgical intervention.

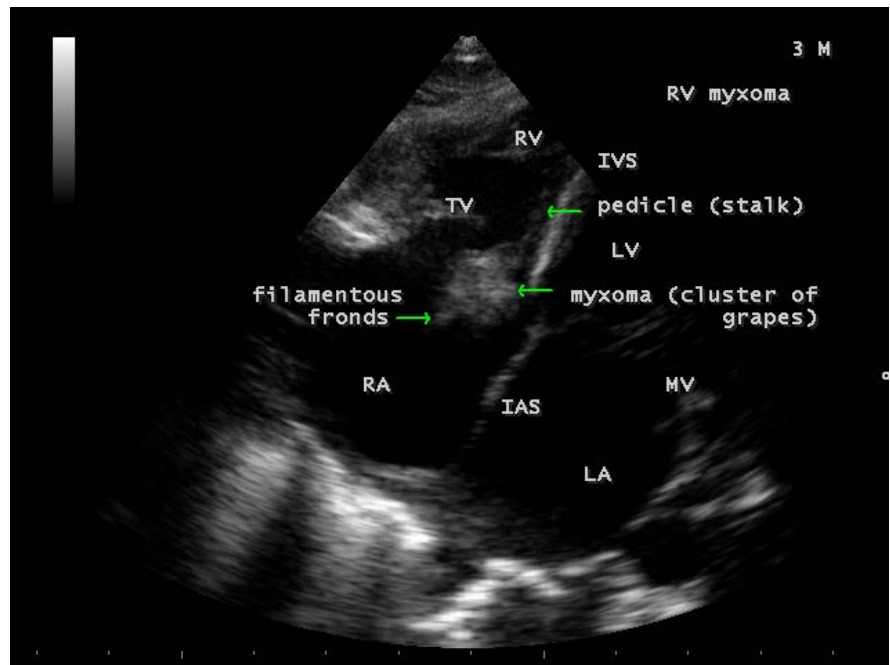


Figure 13. Showing the RV (right ventricular) myxoma attached to the interventricular septum by a pedicle (left upper arrow) and appears as “cluster of grapes” (left lower arrow) with filamentous fronds (right arrow) in a 3-year-old male child.

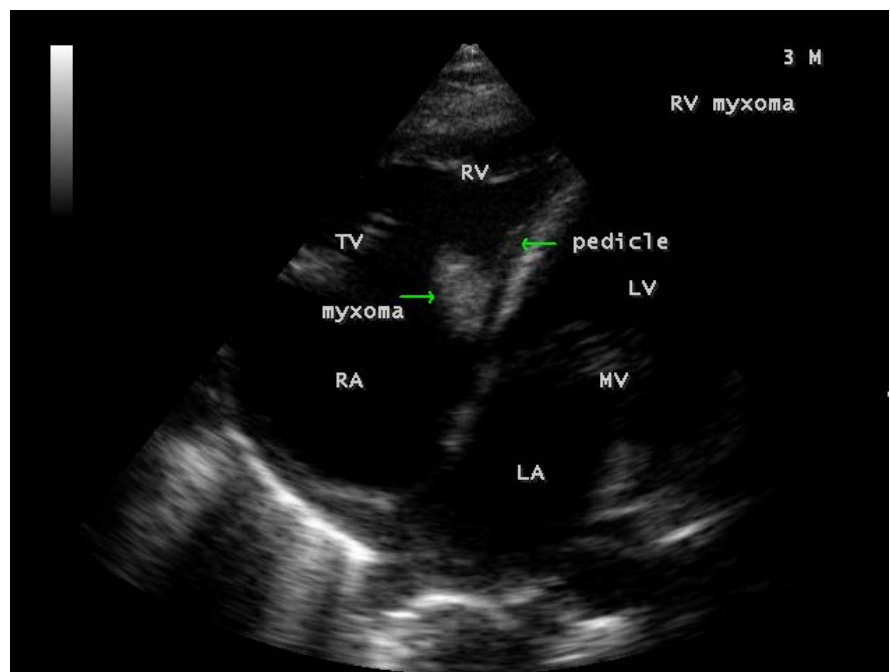


Figure 14. Showing the RV (right ventricular) myxoma (right arrow) attached to the interventricular septum by a pedicle (left arrow).

3. Discussion

3.1. Review of Literature

Lewis and Grant were the first to describe the infective endocarditis [14]. Gould,

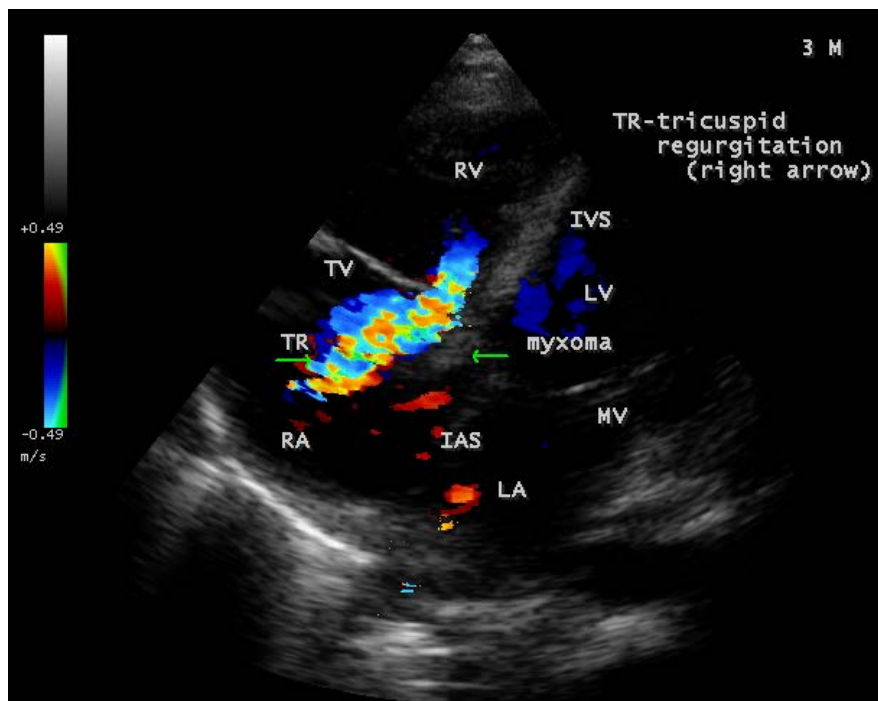


Figure 15. Showing the severe tricuspid regurgitation (right arrow) with a mass lesion (left arrow) in a 3-year-old male child.

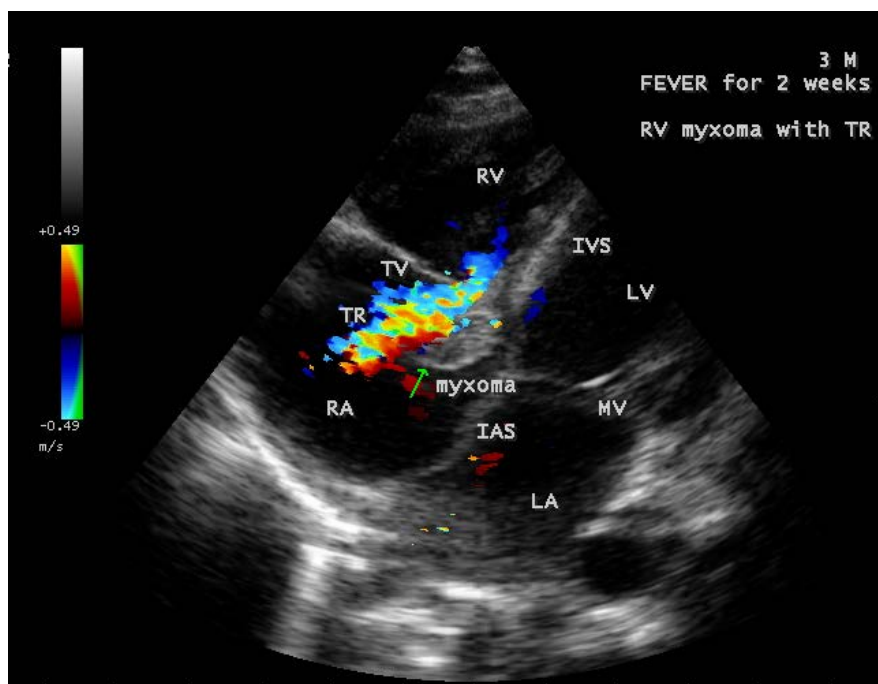


Figure 16. Showing the moderate tricuspid regurgitation with a mass lesion in a 3-year-old male child. Arrow showing the “snowball” appearance of myxoma.

et al. [15] found that bacteria most frequently responsible for endocarditis (e.g., viridans streptococci) displayed a propensity for adherence to human valves. There are only few reports of large tricuspid valve vegetations in the literature.

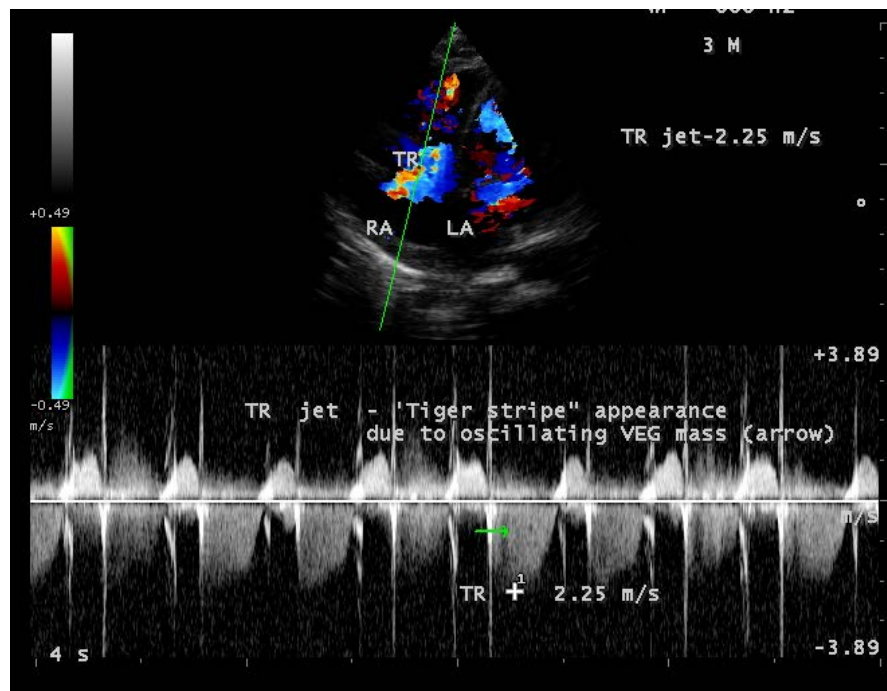


Figure 17. Spectral Doppler showing the “tiger-stripe” appearance of the tricuspid regurgitant jet (arrow) due to the oscillating mass across the valve.

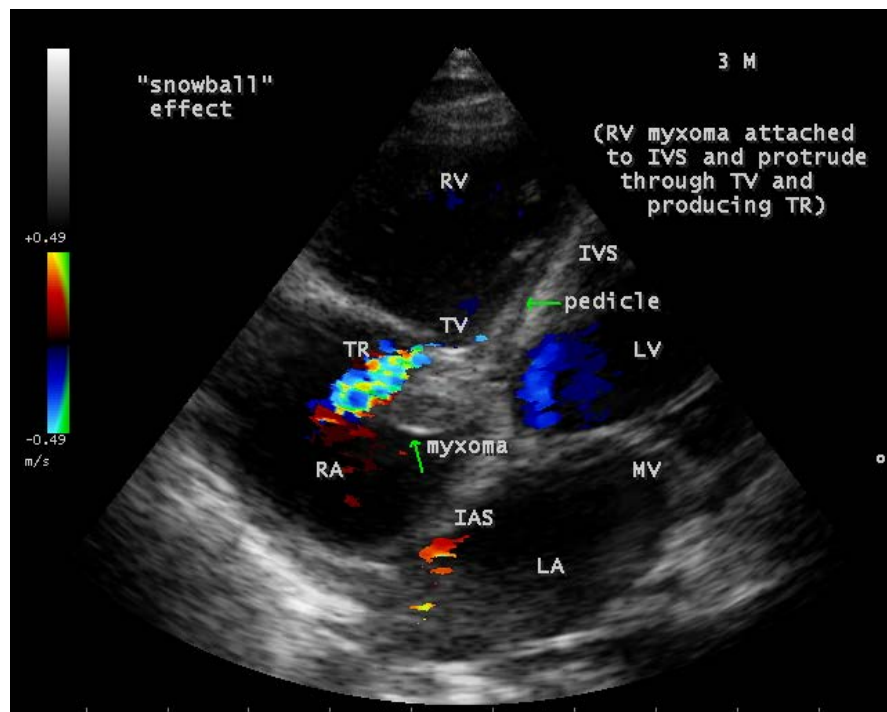


Figure 18. Showing the mild tricuspid regurgitation with a mass lesion in a 3-year-old male child. Upper arrow showing the pedicle of myxoma attached to the interventricular septum (IVS). Lower arrow showing the “snowball” appearance of myxoma.

Song, *et al.* [16] reported a vegetation on tricuspid valve in a 33-year old male, presented with right-sided heart failure and Furui, *et al.* [17] reported a 1.5 cm

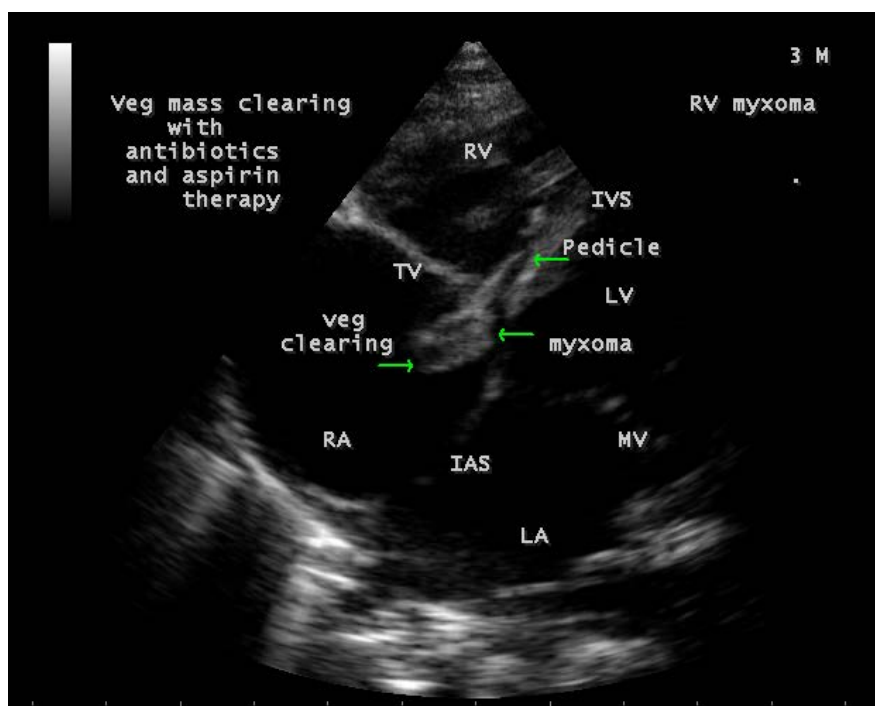


Figure 19. Showing the clearance of vegetation from the myxoma due to antibiotics and aspirin therapy (right arrow). Upper arrow showing the pedicle of myxoma attached to the interventricular septum (IVS).

vegetation on tricuspid valve in a 71-year-old male who developed ventricular septal perforation caused by right-sided infective endocarditis.

3.2. Etiopathogenesis

The endothelial lining of the heart and its valve is normally resistant to infection with bacteria and fungi. When there is a pressure gradient with resultant turbulence of blood flow, which against either the mural endocardium or vascular endothelium results in tissue damage due to high velocity jet (“jet lesions”). Endocarditis begins as endothelial damage, followed by focal adherence of platelets and fibrin. The initial sterile platelet-fibrin nidus, first recognized by Angrist [18] and called as ‘nonbacterial thrombus’, then becomes infected by microorganisms circulating in the blood stream. Platelet-fibrin nidus involves a complex interactions of the components of microbial cell wall such as dextran in the cell wall of gram positive organisms and valvular endothelium [19], intrinsic binding affinity to fibronectin [20] and glucosyl transferases which may act as “modulins” to express various cytokines (interleukin-6) or adhesions that in turn further recruit leukocytes into the vegetation [21]. The other factors which mediate adherence include fibrinogen, laminin, type 4 collagen which are the components found in the damaged endothelium or platelet-fibrin aggregate. Following colonization of platelet-fibrin aggregate [22], microbial growth results in the secondary accumulation of platelets and fibrin to form a vegetation. It consists of bacteria encased in a meshwork of platelets and fibrin, serves as a barrier to

host defences and it is not vascularized.

The propensity for vegetation to form at specific sites may also relate to a decrease in lateral pressure downstream from the regurgitant flow, which causes a decrease in the perfusion of intimal lining at these sites [23]. Tricuspid vegetations are large due to the low pressure in right heart chambers, allowing them to grow and may be in excess of 2 cm [24]. Vegetation often prevent proper valvular leaflet or cusp coaptation, thereby causing valvular incompetence resulting in congestive heart failure [25] or leaflet perforation secondary to vegetation growth [26] with recruitment of matrix metalloproteinases (MMPs) and eventually destroy the collagen. Pneumonia or septic pulmonary embolism resulting from dislodgement of vegetative material is common. Recurrent pulmonary events, anemia and microscopic hematuria, the so called “tricuspid syndrome” is a feature of right-sided tricuspid valve endocarditis [27].

Tricuspid valve endocarditis may occur in community-acquired or hospital-acquired infection and the organisms responsible for both are shown in **Table 1**.

Cardiac myxomas are seen initially with protean manifestations that mimic many disease processes. About 5% of myxomas are found in the ventricles, usually solitary and attached to the interventricular septum by a pedicle [28]. Small myxomas are silent and manifest if they become infected or embolize. The systemic manifestations consists of fever, weight loss, malaise, with leukocytosis, thrombocytopenia, elevated ESR (erythrocyte sedimentation rate), increase in gamma globulins, polycythemia and Raynaud’s phenomenon [29] may occur in 90% of myxomas.

3.3. Echocardiographic Features

The most common and direct evidence of infective endocarditis is the vegetation and it must be at least 3 to 6 mm in size to be reliably seen. Transthoracic echocardiography (TTE) can, at best, detect vegetation to a minimum size of 2 mm and it is usually the more sensitive technique, with sensitivities in children up to 80% [30]. The characteristic echo appearance of a vegetation is of an echogenic mass, irregular in shape, attached to the “upstream” side of a valve leaflet, *i.e.*, atrial side of atrioventricular valves, most commonly at the coaptation line and prolapsed through the tricuspid valve as shown in **Figure 3** and **Figure 4**. The

Table 1. Showing the organisms responsible for infective endocarditis. MRSA—methicillin resistant staphylococcus aureus.

Organism	Community acquired endocarditis (IV drug users)	Hospital acquired endocarditis (intravascular devices)
Staphylococcus aureus	30% - 50% (MRSA-minority)	60% - 80% (MRSA-majority)
α -hemolytic streptococci (viridans)	10% - 35%	<5%
Enterococcus	5% - 10%	5%
Culture negative	5% - 30%	5%
Fungi	<5%	10%
Staphylococcus epidermidis (coagulase negative)	<5%	<5%
Others (Escherichia coli, Klebsiella, Corynebacterium)	<5%	5% - 10%

vegetation vary in size, sometimes reaching 2 - 3 cm in diameter and can be so big that they are mistaken for a cardiac tumor as shown in **Figures 5-9**.

The gold standard for diagnosis of infective endocarditis is the modified Duke criteria [31] and it emphasized the essential relationship between clinical and echocardiographic findings. Duke's criteria have been predominantly applied for left-sided endocarditis and have not been studied specifically in tricuspid valve endocarditis [32] and it may be difficult to determine [33] in its diagnosis.

Echocardiography remains the most safe and simple noninvasive method to diagnose the presence of an intracavitary myxoma [34]. Myxomas are typically nonhomogeneous in texture with lucent centers or areas of calcification. They may be smooth surfaced but are more often irregularly shaped with filamentous fronds or have the appearance of "cluster of grapes" as shown in **Figure 13** and **Figure 14**. They are either sessile or pedunculated with a distinct stalk (pedicle), variably friable and originates from subendocardial nests of primitive mesenchymal cells. The tumor arising from the ventricular cavity was attached by a stalk to the interventricular septum as shown in **Figures 10-14**.

Vegetation can occur on any surface [35]. Endocarditis usually begins as a mechanical traumatic event during the protrusion of myxoma through the tricuspid valve and the vegetations are attached to its surface as shown in **Figures 10-12**. The tumor mass is seen to oscillate into the right atrium through the tricuspid valve and producing regurgitation as shown in **Figure 15** and **Figure 16** and the oscillations visible as "tiger-stripe" appearance in the Spectral Doppler imaging as shown in **Figure 17**.

3.4. Management

3.4.1. Medical Therapy

Fever, multiple pulmonary emboli and sustained bacteremia by staphylococcus aureus are the signs of clinical alert for right-sided endocarditis [36]. After the diagnosis of tricuspid valve endocarditis, medical treatment with antibiotics is indicated and should be continued for 4 to 6 weeks until the signs of infection disappear. Prolonged therapy is necessary since very high densities of bacteria approaching 10^9 to 10^{10} organisms per gram of tissue, become metabolically dormant and are difficult to eradicate since the organisms are relatively protected within the vegetation from phagocytic and other host defence mechanisms. Bactericidal antibiotics or antibiotic combination rather than bacteriostatic agents with high serum concentration may reach the central area of avascular vegetation by passive diffusion [37]. In small children, intravenous antibiotics with the use of heparin lock devices are preferred and home intravenous therapy is generally not recommended.

Uncomplicated tricuspid valve endocarditis is successfully treated medically in 80% of cases. Given the low likelihood of adherence to 4 - 6 week therapy, shorter courses of therapy with a combination of β -lactam with or without an aminoglycoside (for 2 weeks) have become an accepted standard in methicillin-sensitive staphylococcus aureus native valve endocarditis. Experience with 2

weeks regimen in children is limited, but it appears promising [38]. Short course therapy should not be used for patients infected with a relatively penicillin-resistant organism, nutritionally deficient streptococcus and a presence of vegetation visible by echocardiography.

Unless the clinical or epidemiologic clues suggest an etiological diagnosis, the recommended treatment for culture-negative native valve endocarditis is ampicillin plus gentamycin. Ceftriaxone can be used in this regimen instead of ampicillin. Isolated native non-rheumatic fungal tricuspid valve endocarditis with a large and more friable vegetation is the most severe form of endocarditis. *Aspergillus* species (mostly *Aspergillus fumigatus*) are the second most common fungi isolated from cardiac vegetation (25%), whilst *Candida* accounts for 53% and *Histoplasma* for 6% of cases of fungal endocarditis. Amphotericin B has been the 'gold standard' treatment for *Aspergillus* endocarditis, despite its known poor penetration into vegetation [39]. The role of new echinocandins such as caspofungin has been recently approved and a combination of voriconazole with caspofungin is an alternative approach with promising results in refractory *Aspergillus* infection [40].

3.4.2. Aspirin Therapy

Bacteria-platelet interaction appears to be important in both the induction of a vegetation and its enlargement after colonization. Acetylsalicylic acid (aspirin) was shown to have an effect on both platelets and organisms in a rabbit model of staphylococcus aureus endocarditis. Animals treated with aspirin had reduction in the weight of valvular vegetation, its growth, density of bacteria and a decrease in embolic events compared to controls [41].

3.4.3. Surgical Therapy

Although tricuspid valve endocarditis is successfully treated medically in about 75% of patients, conservative treatment is not always effective, and surgical treatment is required in approximately the remaining 25% [42] [43]. The indications of surgery in right-sided infective endocarditis are not well defined, but it should be considered in the following circumstances as shown in **Table 2** [44].

Timing of surgery in right-sided infective endocarditis is less clear. The optimum timing for the surgery was also stated previously [45]. The ESC (European Society of Cardiology) guidelines classified surgical indications in infective endocarditis as emergent (within 24 hours), urgent (within a few days), and

Table 2. Indications of surgery in right-sided infective endocarditis.

Indications of surgery in right-sided infective endocarditis

TV (tricuspid valve) vegetation > 20 mm and recurrent septic pulmonary embolism with or without concomitant right heart failure

IE (infective endocarditis) caused by microorganisms that are difficult to eradicate (e.g. fungi) or bacteremia for at least 7 days (e.g. *Staphylococcus aureus*, *Pseudomonas aeruginosa*) despite adequate antimicrobial therapy

Right heart failure secondary to severe tricuspid regurgitation with poor response to diuretic therapy.

elective (after 1 to 2 weeks of antibiotic therapy). The AHA/ACC guidelines define early surgery as occurring during the initial hospitalization and before completion of a full therapeutic course of antibiotics. Early surgery of tricuspid valve infective endocarditis is considered if there is infected indwelling catheters or pacing leads and a dehiscence of prosthetic valve due to perivalvular infection (unstable prostheses) [46]. Vegetation size is a questionable indication for surgery and a study by Lutas, *et al.* [47] showed that the size of vegetation is not an indication for surgery by itself. According to the current guidelines, patients with large vegetation (>15 mm) should be operated [48] [49] on urgently (within days) and those with fungal infection that are resistant to medical treatment should be operated during the hospitalization period.

Tricuspid valve infective endocarditis can be especially perilous because the proliferation of growth called vegetation, may cause the valve to regurgitate. After the infection causes structural damage to the valve, antibiotics alone cannot cure and require surgery to stem the “snowball effect” the leaking valve as in **Figure 18** [50]. The principles of surgery include radical debridement of vegetation/infected tissue and valve repair using a variety of techniques [51] [52] such as autologous pericardial patch augmentation of the destroyed leaflets, implantation of an annuloplasty ring and expanded polytetrafluoroethylene neochord whenever possible. If the damage is too severe, the valve should be excised and replaced with a bovine pericardial valve, a bioprosthesis preferably since there is a high risk of thrombosis due to low velocity of blood flow in right-sided chambers. The complete excision of the tricuspid valve was first described by Arbulo, *et al.* [53] and valvectomy accounts for 7.2% of operations performed for tricuspid valve endocarditis in North America [54]. TV (tricuspid valve) excision should be limited to extreme cases only when the pulmonary artery pressure and vascular resistance are not elevated, and subsequent valve replacement should be considered once the infection is resolved. Fungal endocarditis remains a ‘stand-alone’ indication for surgical replacement of an infected valve. Tricuspid valve replacement resulted heart block in 16% of cases and epicardial lead placement should be considered since the placement of permanent endocardial leads across a bioprosthesis may cause regurgitation and reduces the prosthesis durability due to leaflet fibrosis and retraction.

Prompt surgical removal of the intracardiac tumor is mandatory as systemic emboli or valvular obstruction can occur unexpectedly. The first surgical excision of a myxoma was performed in 1954 [55]. The myxoma is removed en bloc with its attachment to the interventricular septum [56] and every effort should be made to avoid fragmentation and embolization. Laser photocoagulation of a 1-cm area around the stalk attachment site has also been suggested as a way of eradicating pretumorous cells [57].

3.4.4. Interventional Therapy

Surgical management of acute infective endocarditis is a major challenge. AngioVac [58], a suction thrombectomy device approved for removal of undesirable intra-

vascular material, such as clots, tumors, or any foreign material in the vascular system. It can be an option in the management of right-sided infective endocarditis in critically ill patients with high surgical risk. Debulking the infection site and achieving lower bacterial load can increase antibiotic efficacy. Percutaneous vegetation removal has been used as a bridge to surgery in acute tricuspid valve endocarditis [59] [60].

3.5. Outcome

The long-term prognosis of patients with negative blood culture infective endocarditis has been found to be similar to that of patients with positive blood culture infective endocarditis across all age groups [61]. Tricuspid valve infective endocarditis has a benign prognosis and an in-hospital mortality of <10%, long-term mortality of <15% and the reported operative mortality ranges from 9 to 15% for isolated tricuspid valve endocarditis [62]. The presence of vegetation or vegetation size could be a predictor of outcome for a subgroup of patients who are at risk for the development of complications [63] [64]. In-hospital mortality was higher in those with vegetations larger than 10 mm and mortality rate increases even with smaller vegetations [65]. In some studies, the relationship between vegetation size and the likelihood of mortality as assessed as >15 mm [66] and, >20 mm and fungal etiology [67] are the predictors of increase in mortality rate. Right heart failure is also a predictor of poor outcome in right-sided endocarditis [68] [69].

Numerous reports documented complete cure of myxoma with follow-up period of 10 to 15 years [70] [71] and the surgical results are excellent with resolution of associated symptoms [72]. In about 1 to 5% of cases, a recurrence or secondary cardiac myxoma has been reported after resection of the initial tumor [73] [74].

3.6. Case Analysis

A 3-year-old febrile male child despite antibiotic treatment for 2 weeks with an auscultatory findings of a right-sided regurgitant lesion as evidenced by grade 3/6 systolic murmur and a mass lesion as evidenced by tumor “plop” in lower left sternal border, suggesting a right-sided infective endocarditis of acute onset clinically. The non-drug users are generally present with symptoms of >2 weeks duration [75] and if tricuspid valve is involved, heart murmurs are found with variable frequency in 35% to 72% of cases [76]. The source of infection is from in-situ intravenous canulas and the blood cultures were negative due to prior antibiotic therapy. Elevated total leukocyte count up to 42,700 cells/cubic mm of blood was due to leukemoid reaction as the result of infection. The mass lesion can be confused as valvular vegetation by echocardiography as shown in **Figures 5-9**. The vegetation is adherent to the mass, which is attached to the interventricular septum by a pedicle suggesting the RV (right ventricular) myxoma as in **Figures 10-14** and it is masquerading as tricuspid valve vegetation in **Figures 5-9**.

The infective process and trauma due to mass lesion results in significant valve damage and producing moderate to severe tricuspid regurgitation as shown in **Figures 15-17**.

Right-sided endocarditis, often allows time for medical treatment to take effect because the regurgitant lesion is well tolerated. Hence, it is recommended to treat medically with antibiotics initially before sending the patient for surgery. With effective treatment, regurgitant lesion decreased as in **Figure 18**, the vegetation gradually shrink and disappeared as shown in **Figure 19** even though disappearance of a vegetation should raise a suspicion that the vegetation has broken free and embolized elsewhere, but there was no signs of septic pulmonary emboli since the X-ray chest PA view revealed normal as in **Figure 2**. Because there is a high risk of relapse after short-term antibiotic therapy, prolonged therapy is recommended for a minimum period of 4 weeks [77] with an advise of surgical removal of tumor in this child.

3.7. Screening of Population

Calcification is present approximately in 10% to 20% of cardiac myxomas and right atrial myxomas appear to calcify more readily than left atrial myxoma [78] as shown in **Figure 20** and it is associated with rheumatic AV valve (mitral and tricuspid) regurgitation as in **Figure 21** in a 28-year-old female. A left atrial myxoma, attached to fossa ovalis, is associated with rheumatic AV valve stenosis (mitral and tricuspid) and tricuspid regurgitation as shown in **Figures 22-25** (Note: Thrombus typically produces a “layered appearance” and is generally situated in the posterior portion of the atrium).

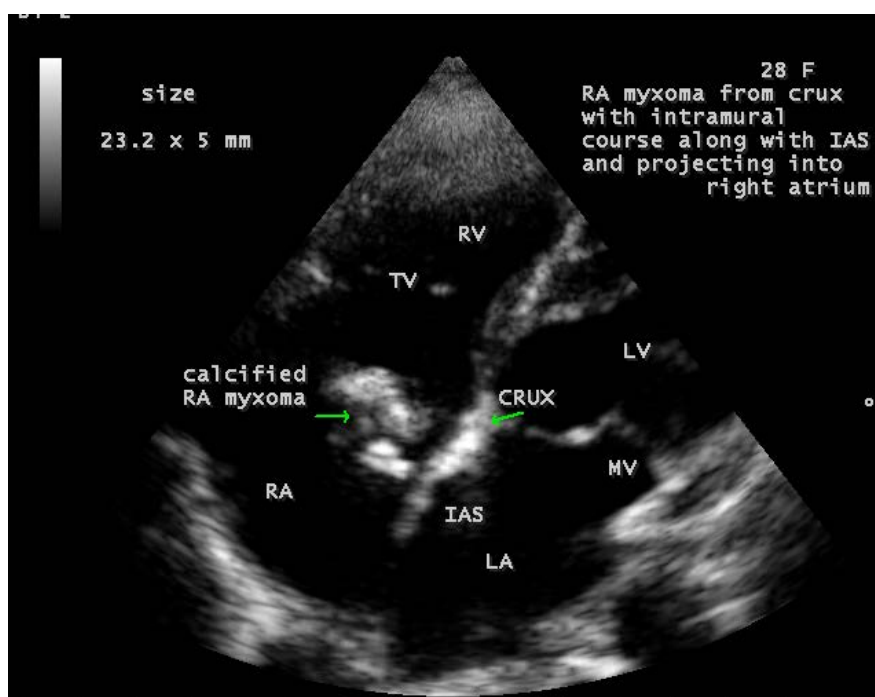


Figure 20. Showing the calcified right atrial myxoma (arrow) in a 28-year-old female.

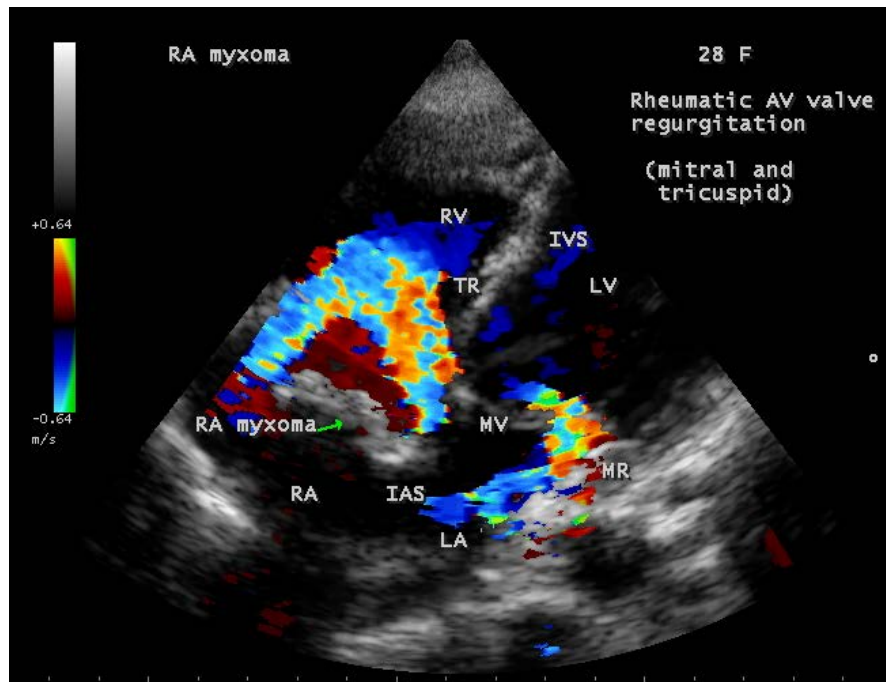


Figure 21. Showing the rheumatic AV valve (mitral and tricuspid) regurgitation associated with calcified right atrial myxoma (arrow) in a 28-year-old female.

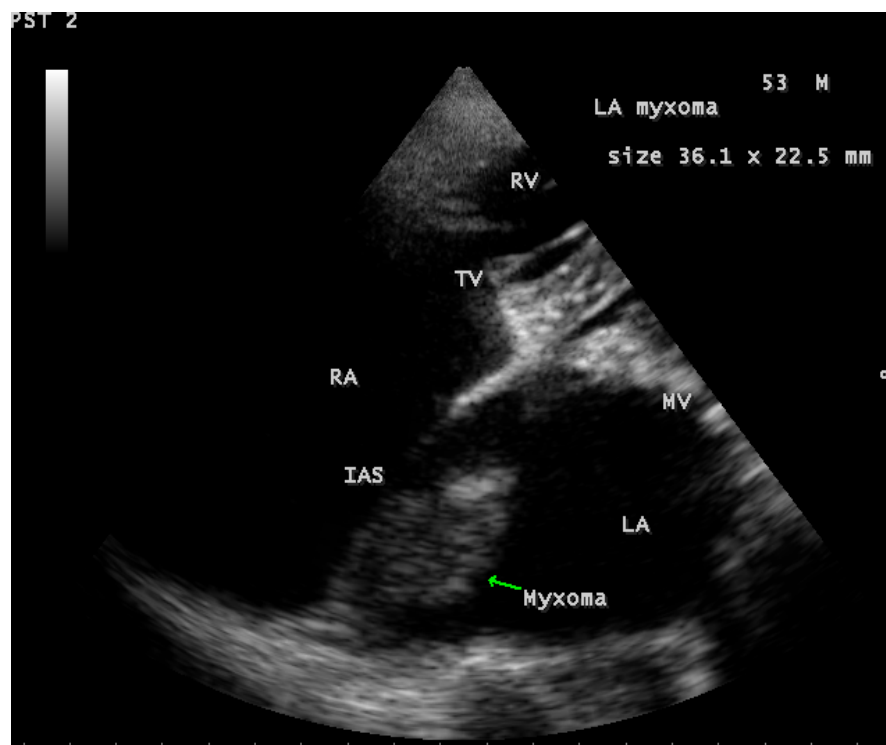


Figure 22. Tilted apical view showing the left atrial myxoma (arrow) arising from the fossa ovalis of the interatrial septum in a 53-year-old male.

A vegetation on pulmonary valve in a 1-year-old febrile male with different shapes are shown in **Figures 26-29**.

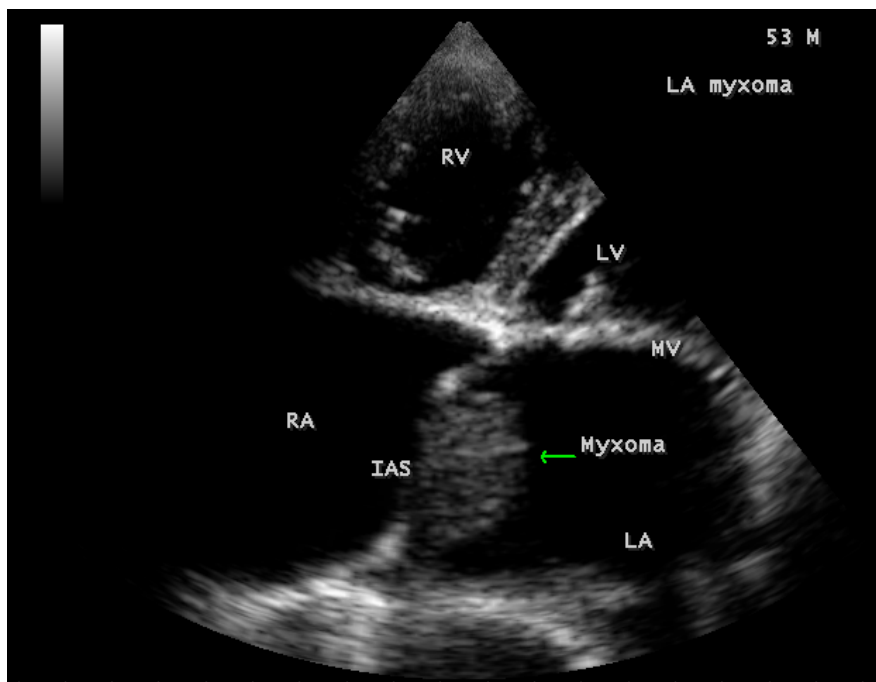


Figure 23. Apical view showing the left atrial myxoma (arrow) arising from fossa ovalis of interatrial septum (IAS) in a 53-year-old male.

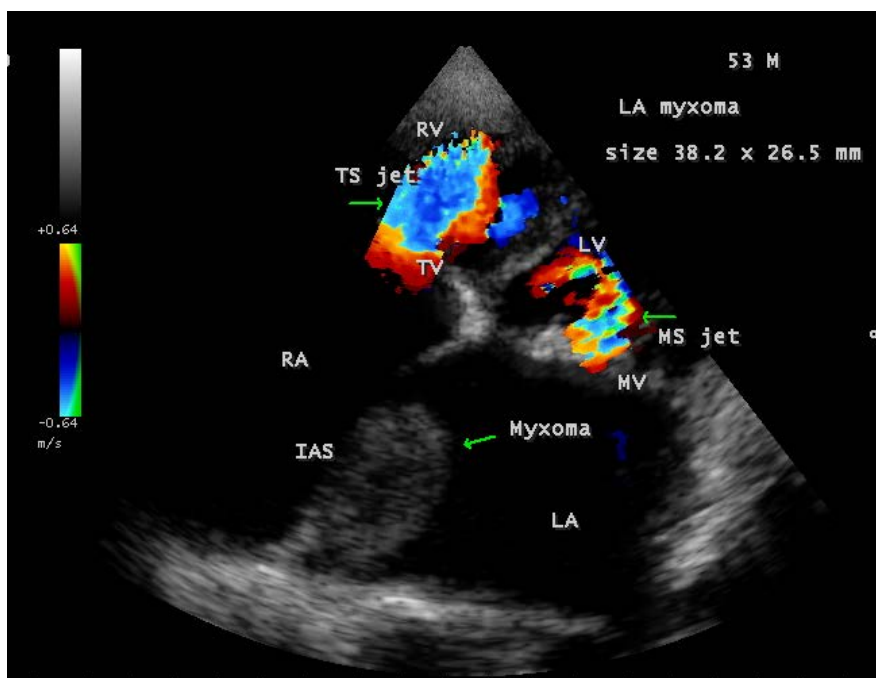


Figure 24. Showing the left atrial myxoma (lower arrow) associated with rheumatic AV valve stenosis (mitral (left upper arrow) and tricuspid (right upper arrow)) in a 53-year-old male.

4. Conclusion

Right-sided endocarditis is generally considered to have a better prognosis and the initial approach to the treatment is conservative with antibiotics according to

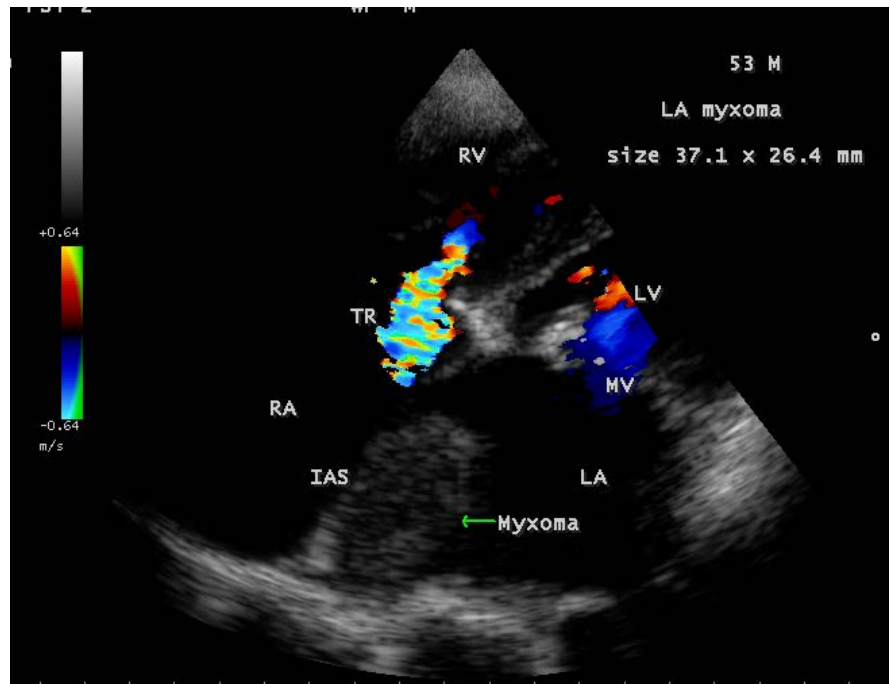


Figure 25. Showing the left atrial myxoma (arrow) associated with rheumatic tricuspid regurgitation (TR) in a 53-year-old male.

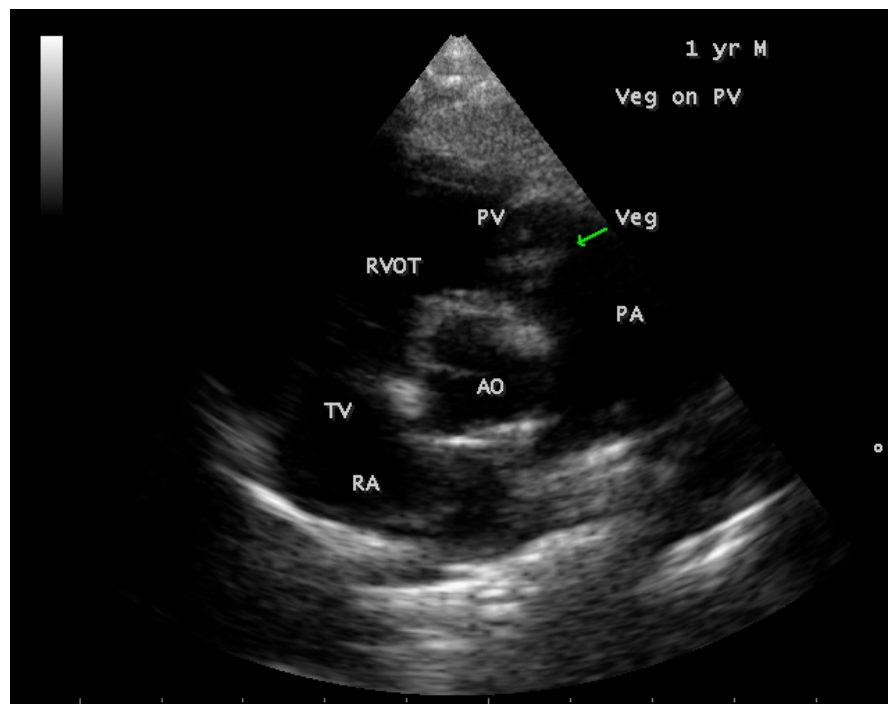


Figure 26. Short axis view showing the vegetation (arrow) on pulmonary valve in a 1-year-old febrile male.

ESC (European Society of Cardiology) guidelines. The medical treatment yielded very good results in this case as the disappearance of vegetation mass as shown in **Figure 19**. Even though optimum management of tricuspid valve infective

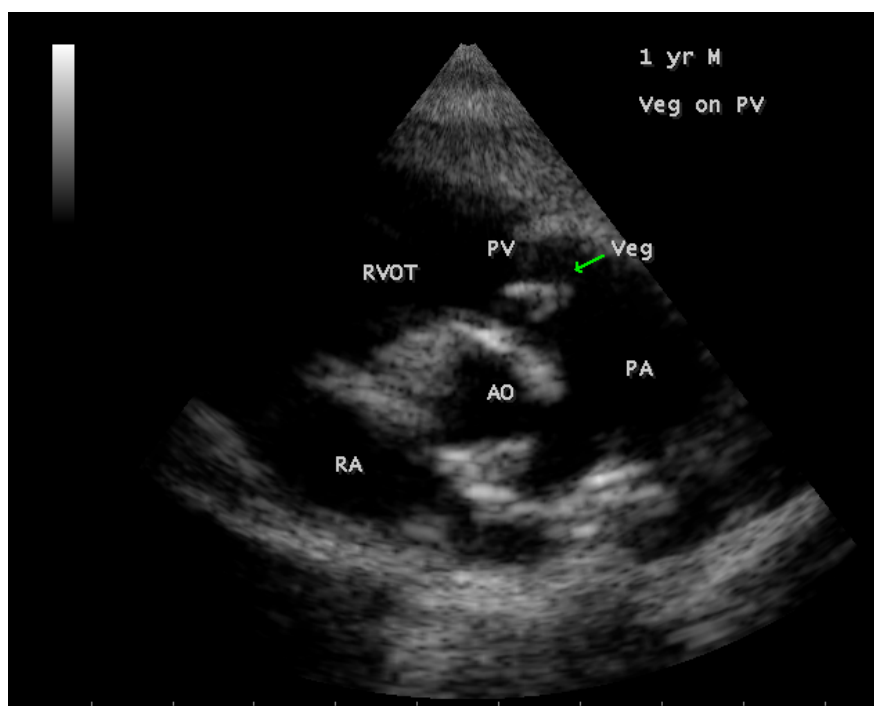


Figure 27. Short axis view showing the vegetation (arrow) on pulmonary valve in a 1-year-old febrile male.

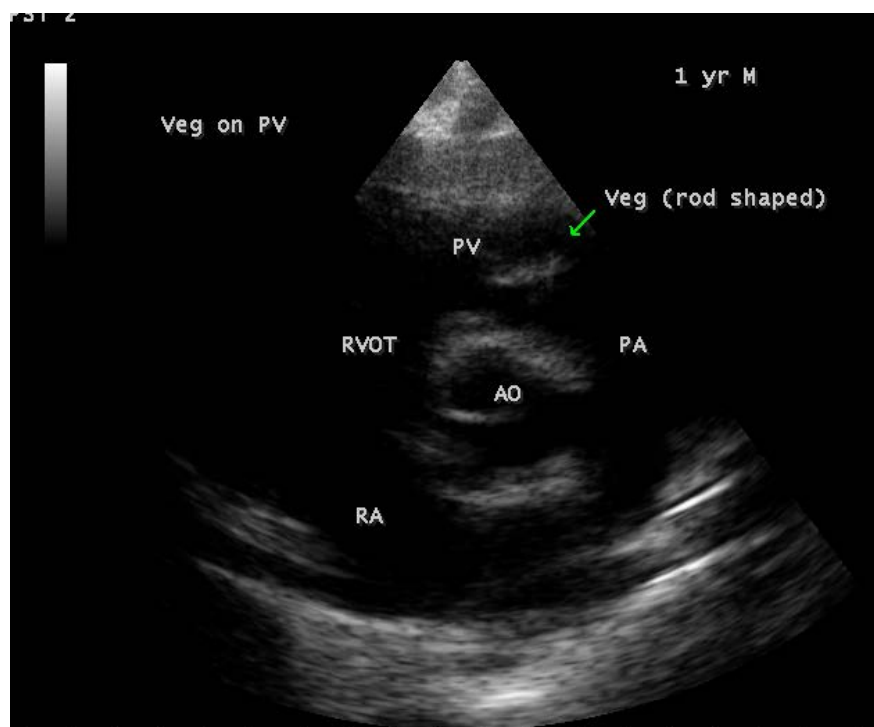


Figure 28. Short axis view showing the vegetation (arrow) on pulmonary valve in a 1-year-old febrile male and it is “rod shaped”.

endocarditis has not yet been defined, it is a serious and potentially lethal condition in an infant or child [79] and so early surgical intervention to remove the

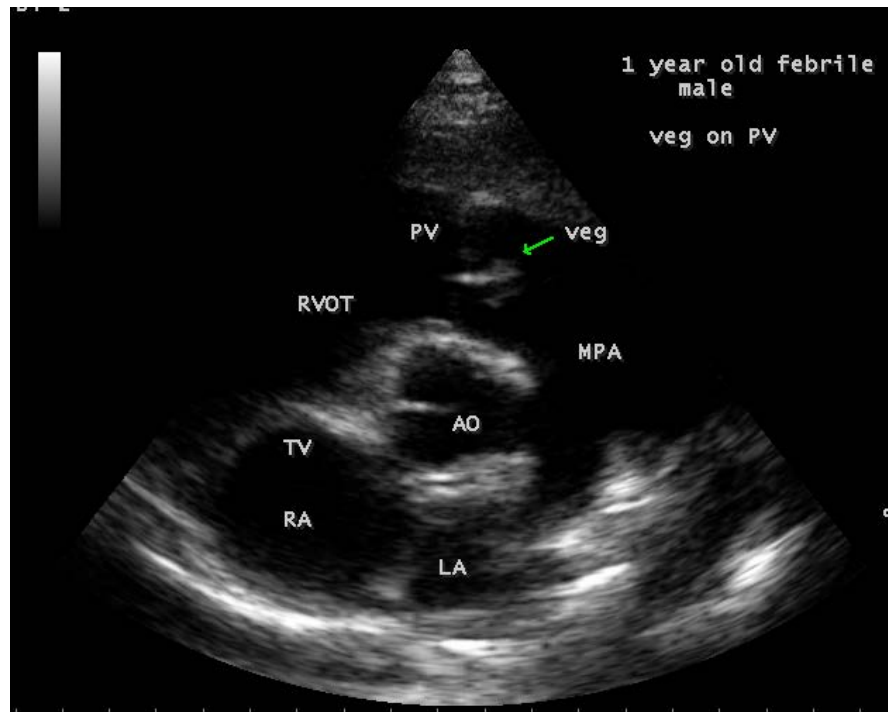


Figure 29. Short axis view showing the vegetation (arrow) on pulmonary valve in a 1-year-old febrile male and it is “arrow head” appearance.

large obstructive vegetation is indicated. The surgical treatment can be performed with low risk and good early, mid and long-term results [80].

References

- [1] Watanakunakorn, C. and Burkert, T. (1993) Infective Endocarditis at a Large Community Teaching Hospital, 1980-1990. A Review of 210 Episodes. *Medicine (Baltimore)*, **72**, 90-102. <https://doi.org/10.1097/00005792-199303000-00003>
- [2] Fonager, K., Lindberg, J., Thulstrup, A.M., Pedersen, L., Schonheyder, H.C. and Sorensen, H.T. (2003) Incidence and Short-Term Prognosis of Infective Endocarditis in Denmark, 1980-1997. *Scandinavian Journal of Infectious Diseases*, **35**, 27-30. <https://doi.org/10.1080/0036554021000026993>
- [3] Walpot, J., Blok, W., Von Zwienen, J., Klazen, C. and Amsel, B. (2006) Incidence and Complication Rate of Infective Endocarditis in the Dutch Region of Walcheren: A 3-Year Retrospective Study. *Acta Cardiologica*, **61**, 175-181. <https://doi.org/10.2143/AC.61.2.2014331>
- [4] Burke, A.P., Kalra, P., Li, L., Smialek, J. and Virmani, R. (1997) Infectious Endocarditis and Sudden Unexpected Death: Incidence and Morphology of Lesions in Intravenous Addicts and Non-Drug Abusers. *Journal of Heart Valve Disease*, **6**, 198-203.
- [5] Habib, G., Lancellotti, P., Antunes, M.J., *et al.* (2015) ESC (European Society of Cardiology) Guidelines for the Management of Infective Endocarditis. *European Heart Journal*, **36**, 3075-3128. <https://doi.org/10.1093/eurheartj/ehv319>
- [6] Murdoch, D.R., Corey, G.R., Hoen, B., *et al.* (2009) Clinical Presentation, Etiology, and Outcome of Infective Endocarditis in the 21st Century: The International Collaboration on Endocarditis-Pro prospective Cohort Study. *Archives of Internal Medicine*

- cine*, **169**, 463-473. <https://doi.org/10.1001/archinternmed.2008.603>
- [7] Stull, T.L. and LiPuma, J.J. (1992) Endocarditis in Children. In: Kaye, D., Ed., *Infective Endocarditis*, 2nd Edition, Raven, New York, 313-327.
- [8] Chen, S.C., Dwyer, D.E. and Sorrell, T.C. (1992) A Comparison of Hospital and Community-Acquired Infective Endocarditis. *American Journal of Cardiology*, **70**, 1449-1452. [https://doi.org/10.1016/0002-9149\(92\)90298-D](https://doi.org/10.1016/0002-9149(92)90298-D)
- [9] Osler, W. (1885) Gustonian Lectures on Malignant Endocarditis. *The Lancet*, **1**, 415-418. [https://doi.org/10.1016/S0140-6736\(02\)00827-9](https://doi.org/10.1016/S0140-6736(02)00827-9)
- [10] Bass, N.M. and Sharatt, G.J.P. (1973) Left Atrial Myxoma Diagnosed by Echocardiography with Observations on Tumor Movement. *British Heart Journal*, **35**, 1332-1335. <https://doi.org/10.1136/hrt.35.12.1332>
- [11] Bae, J.M., Choe, Y.H., Hwang, H.W., Kim, J.-S., Kim, W.S., Peck, K.R. and Park, S.-J. (2015) Tumor-Mimicking Large Vegetation Attached to the Tricuspid Valve without Predisposing Factors. A Case Report on CT and Echocardiographic Findings. *Journal of the Korean Society of Radiology*, **73**, 269-273.
- [12] Mazzeffi, M., Reich, D.L., Adams, D.H. and Fischer, G.W. (2011) A Mitral Valve Mass: Tumor, Thrombus, or Vegetation? *Journal of Cardiothoracic and vascular Anesthesia*, **25**, 889-890. <https://doi.org/10.1053/j.jvca.2010.06.009>
- [13] Feigenbaum, H., Armstrong, W.F. and Ryan, T. (2005) Masses, Tumors, and Source of Embolism. In: *Feigenbaum's Echocardiography*, 6th Edition, Chapter 21, Lippincott Williams & Wilkins, Philadelphia, 703.
- [14] Lewis, T. and Grant, R.T. (1923) Observations Relating to Subacute Infective Endocarditis. *Heart*, **10**, 21-77.
- [15] Gould, K., Ramirez-Ronda, C.H., Holmes, R.K., *et al.* (1975) Adherence of Bacteria to Heart Valves *in Vitro*. *Journal of Clinical Investigation*, **56**, 1364-1370. <https://doi.org/10.1172/JCI108216>
- [16] Song, M.H., Usui, M., Usui, A., *et al.* (2001) Giant Vegetation Mimicking Cardiac Tumor in Tricuspid Valve Endocarditis after Catheter Ablation. *Japanese Journal of Thoracic and Cardiovascular Surgery*, **49**, 255-257. <https://doi.org/10.1007/BF02913526>
- [17] Furui, M., Ohashi, T., Yoshida, T., *et al.* (2010) Ventricular Septal Perforation Caused by Right-Sided Infective Endocarditis Associated with Giant Vegetation. *Annals of Thoracic Surgery*, **89**, 959-961. <https://doi.org/10.1016/j.athoracsur.2009.07.054>
- [18] Oka, M. and Angrist, A. (1965) Comparative Histochemical Studies of Nonbacterial and Bacterial Valvular Vegetations. *Laboratory Investigation*, **14**, 48-61.
- [19] Scheld, W.M., Valone, J.A. and Sande, M.A. (1978) Bacterial Adherence in the Pathogenesis of Endocarditis. Interaction of Bacterial Dextran, Platelets, and Fibrin. *Journal of Clinical Investigation*, **61**, 1394-1404. <https://doi.org/10.1172/JCI109057>
- [20] Kuypers, J.M. and Proctor, R.A. (1989) Reduced Adherence to Traumatized Rat Heart Valve by a Low-Fibronectin-Binding Mutant of Staphylococcus Aureus. *Infection and Immunity (American Society for Microbiology)*, **57**, 2306-2312.
- [21] Yeh, C.Y., Chen, J.Y. and Chia, J.S. (2006) Glucosyltransferases of Viridans Group Streptococci Modulate Interleukin-6 and Adhesion Molecule Expression in Endothelial Cells and Augment Monocytic Cell Adherence. *Infection and Immunity*, **74**, 1273-1283. <https://doi.org/10.1128/IAI.74.2.1273-1283.2006>
- [22] Reynon, R.P., *et al.* (2006) Infective Endocarditis. *British Medical Journal*, **333**, 334-339. <https://doi.org/10.1136/bmj.333.7563.334>

- [23] Freedom, L.R. and Valone, J. (1979) Experimental Infective Endocarditis. *Progress in Cardiovascular Diseases*, **22**, 169-180. [https://doi.org/10.1016/0033-0620\(79\)90021-5](https://doi.org/10.1016/0033-0620(79)90021-5)
- [24] Moss, R. and Munt, B. (2003) Injection Drug Use and Right Sided Endocarditis. *Heart*, **89**, 577-581. <https://doi.org/10.1136/heart.89.5.577>
- [25] Weinstein, L. (1986) Life-Threatening Complications of Infective Endocarditis and Their Management. *Archives of Internal Medicine*, **146**, 953-957. <https://doi.org/10.1001/archinte.1986.00360170183025>
- [26] Yvorchuk, K.J. and Chan, K.L. (1994) Application of Transthoracic and Transesophageal Echocardiography in the Diagnosis and Management of Infective Endocarditis. *Journal of American Society of Echocardiography*, **7**, 294-308. [https://doi.org/10.1016/S0894-7317\(14\)80400-8](https://doi.org/10.1016/S0894-7317(14)80400-8)
- [27] Heydari, A.A., Safari, H. and Sarvghad, M.R. (2009) Isolated Tricuspid Valve Endocarditis. *International Journal of Infectious Diseases*, **13**, e109-e111. <https://doi.org/10.1016/j.ijid.2008.07.018>
- [28] Goodwin, J.F. (1963) Diagnosis of Left Atrial Myxoma. *The Lancet*, **1**, 464-468. [https://doi.org/10.1016/S0140-6736\(63\)92359-6](https://doi.org/10.1016/S0140-6736(63)92359-6)
- [29] Skanse, B., Berg, N.O. and Westfelt, L. (1959) Atrial Myxoma with Raynaud Phenomenon as the Initial Symptom. *Acta Medica Scandinavica*, **164**, 321-324. <https://doi.org/10.1111/j.0954-6820.1959.tb00193.x>
- [30] Van Hare, G.F., Ben-Shachar, G., Liebman, J., *et al.* (1984) Infective Endocarditis in Infants and Children during the Past 10 Years: A Decade of Change. *American Heart Journal*, **107**, 1235-1240. [https://doi.org/10.1016/0002-8703\(84\)90283-7](https://doi.org/10.1016/0002-8703(84)90283-7)
- [31] Li, J.S., Sexton, D.J., Mick, N., *et al.* (2000) Proposed Modifications to the Duke Criteria for the Diagnosis of Infective Endocarditis. *Clinical Infectious Diseases*, **30**, 633-638. <https://doi.org/10.1086/313753>
- [32] Panduranga, P., Al-Abri, S. and Al-Lawati, J. (2013) Intravenous Drug Abuse and Tricuspid Valve Endocarditis: Growing Trends in the Middle East Gulf Region. *World Journal of Cardiology*, **5**, 397-403. <https://doi.org/10.4330/wjc.v5.i11.397>
- [33] Hussain, S.T., Witten, J., Shrestha, N.K., Blackstone, E.H. and Pettersson, G.B. (2017) Tricuspid Valve Endocarditis. *Annals of Cardiothoracic Surgery*, **6**, 255-261. <https://doi.org/10.21037/acs.2017.03.09>
- [34] Liu, H.Y., Panidis, I., Soffer, J. and Dreifus, L.S. (1983) Echocardiographic Diagnosis of Intracardiac Myxomas, Today's Practice of Cardiopulmonary Medicine. *Chest*, **84**, 62-67. <https://doi.org/10.1378/chest.84.1.62>
- [35] Schiller, N.B., Ristow, B. and Ren, X. (2018) Role of Echocardiography in Infective Endocarditis.
- [36] Alarcon, A. and Villanueva, J.L. (1998) Endocarditis in Parenteral Drug Addicts. Right-Sided Endocarditis. Influence of HIV Infection. *Revista Espanola De Cardiologia*, **51**, 71-78.
- [37] Karchmer, A.W. (2001) Infective Endocarditis. In: Braunwald, E., Zipes, D.P. and Libby, P., Eds., *Braunwald Heart Disease. A Textbook of Cardiovascular Medicine*, 6th Edition, Chapter 47, Saunders, Philadelphia, London, 1734.
- [38] Dajani, A.S. and Taubert, K.A. (2001) Infective Endocarditis. In: *Moss and Adams, Heart Disease in Infants, Children, and Adolescents*, 6th Edition, Volume 11, Chapter 65, Lippincott Williams & Wilkins, Philadelphia, 1304.
- [39] Rubinstein, *et al.* (1974) Tissue Penetration of Amphotericin B in Candida Endocarditis. *Chest*, **66**, 376-377. <https://doi.org/10.1378/chest.66.4.376>

- [40] MacCallum, D.M., Whyte, J.A. and Odds, F.C. (2005) Efficacy of Caspofungin and Voriconazole Combinations in Experimental Aspergillosis. *Antimicrobial Agents and Chemotherapy*, **49**, 3697-3701. <https://doi.org/10.1128/AAC.49.9.3697-3701.2005>
- [41] Kupferwasser, L.I., Yeaman, M.R., Shapiro, S.M., *et al.* (1999) Acetylsalicylic Acid Reduces Vegetation Bacterial Density, Hematogenous Bacterial Dissemination, and Frequency of Embolic Events in Experimental Staphylococcus Aureus Endocarditis through Antiplatelet and Antibacterial Effects. *Circulation*, **99**, 2791-2797. <https://doi.org/10.1161/01.CIR.99.21.2791>
- [42] Ozkara, C., Dogan, O.F. and Furat, C. (2012) Isolated Tricuspid Valve Infective Endocarditis in Young Drug Abusers. *World Journal of Cardiovascular Diseases*, **2**, 201-203. <https://doi.org/10.4236/wjcd.2012.23033>
- [43] Gottardi, R., Bialy, J. and Devyatko, E. (2007) Midterm Follow-Up of Tricuspid Valve Reconstruction Due to Active Infective Endocarditis. *Annals of Thoracic Surgery*, **84**, 1943-1948. <https://doi.org/10.1016/j.athoracsur.2007.04.116>
- [44] Nishimura, R.A., Otto, C.M., Bonow, R.O., *et al.* (2014) AHA/ACC Guideline for the Management of Patients with Valvular Heart Disease: Executive Summary. A Report of the American College of Cardiology/American Heart Association Task Force on Practice Guidelines. *Circulation*, **129**, 2440-2492. <https://doi.org/10.1161/CIR.0000000000000029>
- [45] Prendergast, B.D. and Tornos, P. (2010) Surgery for Infective Endocarditis. Who and When? *Circulation*, **121**, 1141-1152. <https://doi.org/10.1161/CIRCULATIONAHA.108.773598>
- [46] Dawood, M.Y., Cheema, F.H., Ghoreishi, M., *et al.* (2015) Contemporary Outcomes of Operations for Tricuspid Valve Infective Endocarditis. *Annals of Thoracic Surgery*, **99**, 539-546. <https://doi.org/10.1016/j.athoracsur.2014.08.069>
- [47] Morokuma, H., Minato, N., Kamohara, K. and Minematsu, N. (2010) Three Surgical Cases of Isolated Tricuspid Valve Infective Endocarditis. *Annals of Thoracic and Cardiovascular Surgery*, **16**, 134-138.
- [48] Habib, G., Hoen, B., Tornos, P., Thuny, F., Prendergast, B., Vilacosta, I., *et al.* (2009) Guidelines on the Prevention, Diagnosis, and Treatment of Infective Endocarditis (New Version 2009). *European Heart Journal*, **30**, 2369-2413. <https://doi.org/10.1093/eurheartj/ehp285>
- [49] Habib, G., Badano, L., Tribouilloy, C., Vilacosta, I., Zamorano, J.L., Galderisi, M., *et al.* (2010) Recommendations for the Practice of Echocardiography in Infective Endocarditis. *European Journal of Echocardiography*, **11**, 202-219. <https://doi.org/10.1093/ejechocard/jeq004>
- [50] Tricuspid Valve Infective Endocarditis (2018) Illuminating Research Focuses On Surgery For Rare Heart Valve Infection. University of Maryland Medical Center, Baltimore.
- [51] Akinosoglou, K., Apostolakis, E., Koutsogiannis, N., *et al.* (2012) Right-Sided Infective Endocarditis: Surgical Management. *European Journal of Cardiothoracic Surgery*, **42**, 470-479. <https://doi.org/10.1093/ejcts/ezs084>
- [52] Tarola, C.L., Losenno, K.L. and Chu, M.W. (2015) Complex Tricuspid Valve Repair for Infective Endocarditis: Leaflet Augmentation, Chordae and Annular Reconstruction. *Multimedia Manual of Cardiothoracic Surgery*.
- [53] Arbulu, A., Holmes, R.J. and Asfaw, I. (1993) Surgical Treatment of Intractable Right-Sided Infective Endocarditis in Drug Addicts: 25-Year Experience. *Journal of*

Heart Valve Disease, **2**, 129-137.

- [54] Gaca, J.G., Sheng, S., Daneshmand, M., *et al.* (2013) Current Outcomes for Tricuspid Valve Infective Endocarditis Surgery in North America. *Annals of Thoracic Surgery*, **96**, 1374-1381. <https://doi.org/10.1016/j.athoracsur.2013.05.046>
- [55] Newman, H.A., Cordell, A.R. and Prichard, R.W. (1966) Intracardiac Myxomas: Literature Review and Report of Six Cases, One Successfully Treated. *Annals of Surgery*, **32**, 219-230.
- [56] Kabbani, S.S. and Cooley, D.A. (1973) Atrial Myxoma: Surgical Considerations. *Journal of Thoracic and Cardiovascular Surgery*, **65**, 731-737.
- [57] Mesnildrey, P., Bloch, G., Cachera, J.P. and Piwnica, A. (1989) Atrial Myxoma: A New Surgical Approach Using Neodymium: Yttrium-Aluminum-Garnet Laser Photocoagulation. *Journal of Thoracic And Cardiovascular Surgery*, **98**, 313-314.
- [58] Talebi, S., Xin Tan, B.E., Gazali, R.M. and Herzog, E. (2017) Last Resort: Successful AngioVac of Fungal Tricuspid Valve Vegetation. *QJM (Quarterly Journal of Medicine): An International Journal of Medicine / Oxford Academic*, **110**, 673-674. <https://doi.org/10.1093/qjmed/hcx126>
- [59] Makdisi, G., Casciani, T., Wozniak, T.C., Roe, D.W. and Hashmi, Z.A. (2016) A Successful Percutaneous Mechanical Vegetation Debulking Used as a Bridge to Surgery in Acute Tricuspid Valve Endocarditis. *Journal of Thoracic Disease*, **8**, E137-E139.
- [60] Thiagaraj, A.K., Malviya, M., Htun, W.W., Telila, T., Lerner, S.A., Elder, M.D., *et al.* (2017) A Novel Approach in the Management of Right-Sided Endocarditis: Percutaneous Vegetectomy Using the AngioVac Cannula. *Future Cardiology*, **13**, 211-217. <https://doi.org/10.2217/fca-2016-0076>
- [61] Burke, A.P. (2016) Pathology of Infectious Endocarditis. *The Heart Org Medscape*.
- [62] Baraki, H., Saito, S., Al Ahmad, A., *et al.* (2013) Surgical Treatment for Isolated Tricuspid Valve Endocarditis-Long-Term Follow-Up at a Single Institution. *Circulation Journal*, **77**, 2032-2037. <https://doi.org/10.1253/circj.CJ-12-1364>
- [63] Mugge, A., Daniel, W.G., Frank, G. and Lichtlen, P.R. (1989) Echocardiography in Infective Endocarditis: Reassessment of Prognostic Implications of Vegetation Size Determined by the Transthoracic and the Transesophageal Approach. *Journal of American College of Cardiology*, **14**, 631-638. [https://doi.org/10.1016/0735-1097\(89\)90104-6](https://doi.org/10.1016/0735-1097(89)90104-6)
- [64] Sanfillipo, A.J., Picard, M.H., Newell, J.B., Rosas, E., Davidoff, R., Thomas, J.D., *et al.* (1991) Echocardiographic Assessment of Patients with Infectious Endocarditis: Prediction of Risk for Complications. *Journal of American College of Cardiology*, **18**, 1191-1199. [https://doi.org/10.1016/0735-1097\(91\)90535-H](https://doi.org/10.1016/0735-1097(91)90535-H)
- [65] Sani, A.T., Mojtavavi, M. and Bolandnazar, R. (2009) Effect of Vegetation Size on the Outcome of Infective Endocarditis in Intravenous Drug Users. *Iranian Journal of Clinical Infectious Diseases*, **4**, 129-134.
- [66] Thuny, F., Di Salvo, G., Belliard, O., Avierinos, J.F., Pergola, V., Rosenberg, V., *et al.* (2005) Risk of Embolism and Death in Infective Endocarditis: Prognostic Value of Echocardiography: A Prospective Multicenter Study. *Circulation*, **112**, 69-75. <https://doi.org/10.1161/CIRCULATIONAHA.104.493155>
- [67] Martin-Daliva, P., Navas, E., Fortun, J., Moya, J.L., Cobo, J., Pintado, V., *et al.* (2005) Analysis of Mortality and Risk Factors Associated with Native Valve Endocarditis in Drug Users: The Importance of Vegetation Size. *American Heart Journal*, **150**, 1099-1106. <https://doi.org/10.1016/j.ahj.2005.02.009>

- [68] Barbour, D.J. and Roberts, W.C. (1986) Valve Excision Only versus Valve Excision plus Replacement for Active Infective Endocarditis Involving the Tricuspid Valve. *American Journal of Cardiology*, **57**, 475-478. [https://doi.org/10.1016/0002-9149\(86\)90776-9](https://doi.org/10.1016/0002-9149(86)90776-9)
- [69] Yee, E.S. and Ullyot, D.J. (1988) Reparative Approach for Right-Sided Endocarditis. Operative Considerations and Results of Valvuloplasty. *Journal of Thoracic and Cardiovascular Surgery*, **96**, 133-140.
- [70] Larsson, S., Lepore, V. and Kennergren, C. (1989) Atrial Myxomas: Results of 25-Years' Experience and Review of the Literature. *Surgery*, **105**, 695-698. [https://doi.org/10.1016/0003-4975\(90\)90253-3](https://doi.org/10.1016/0003-4975(90)90253-3)
- [71] Bortolotti, U., Maraglino, G., Rubino, M., *et al.* (1990) Surgical Excision of Intracardiac Myxoma: A 20-Year Follow-Up. *Annals of Thoracic Surgery*, **49**, 449-453.
- [72] Zitnik, R.S. and Giuliani, E.R. (1970) Clinical Recognition of Atrial Myxomas. *American Heart Journal*, **80**, 689-700. [https://doi.org/10.1016/0002-8703\(70\)90016-5](https://doi.org/10.1016/0002-8703(70)90016-5)
- [73] Waller, D.A., Ettles, D.F., Saunders, N.R. and Williams, G. (1989) Recurrent Cardiac Myxoma: The Surgical Implications of Two Distinct Groups of Patients. *The Thoracic and Cardiovascular Surgeon*, **37**, 226-230. <https://doi.org/10.1055/s-2007-1020322>
- [74] Terada, Y., Wanibuchi, Y., Noguchi, M. and Mitsui, T. (2000) Metastatic Atrial Myxoma to the Skin at 15 Years after Surgical Resection. *Annals of Thoracic Surgery*, **69**, 283-284. [https://doi.org/10.1016/S0003-4975\(99\)01112-1](https://doi.org/10.1016/S0003-4975(99)01112-1)
- [75] Stimmel, B., Donoso, E. and Dack, S. (1973) Comparison of Infective Endocarditis in Drug Addicts and Nondrug Users. *American Journal of Cardiology*, **32**, 924-929. [https://doi.org/10.1016/S0002-9149\(73\)80159-6](https://doi.org/10.1016/S0002-9149(73)80159-6)
- [76] Levine, D.P., Crane, L.R. and Zervos, M.J. (1986) Bacteremia in Narcotic Addicts at the Detroit Medical Center. II. Infectious Endocarditis: A Prospective Comparative Study. *Reviews of Infectious Diseases*, **8**, 374-396. <https://doi.org/10.1093/clinids/8.3.374>
- [77] Abe, K., Nakamura, S., Ninomiya, T., *et al.* (1996) Infective Endocarditis Caused by Campylobacter Fetus after Allogeneic Tooth Transplantation: A Case Report. *British Journal of Oral and Maxillofacial Surgery*, **34**, 230-234. [https://doi.org/10.1016/S0266-4356\(96\)90275-2](https://doi.org/10.1016/S0266-4356(96)90275-2)
- [78] Tally, J.D. and Wenger, N.K. (1987) Atrial Myxoma: Overview, Recognition, and Management. *Comprehensive Therapy*, **13**, 12-18.
- [79] Levin, S.E., Dansky, R., Benatar, A. and Milner, S. (1992) Tricuspid Valve Endocarditis on a Healthy Valve-Potentially Lethal in Infants and Young Children. *Cardiology in the Young*, Cambridge Core, **2**, 191-195.
- [80] Musci, M., Siniawski, H., Pasic, M., *et al.* (2007) Surgical Treatment of Right-Sided Active Infective Endocarditis with or without Involvement of the Left Heart: 20-Year Single Center Experience. *European Journal of Cardio-Thoracic Surgery*, **32**, 118-125. <https://doi.org/10.1016/j.ejcts.2007.02.034>